

An unusual cause of massive hemoptysis

Silvia Maestroni,¹ Martino Cellerini,² Antonio Brucato¹

¹Department of Internal Medicine; and ²Department of Neuroradiology, Papa Giovanni XXIII Hospital, Bergamo, Italy

ABSTRACT

A 65-year-old woman presented with recurrent hemoptysis. Four years earlier she had been treated (surgery plus radio-chemotherapy) for a cervical esophageal cancer with regional lymph nodes metastasis. Endoscopies showed areas of recent bleeding in the right pharynx. A 3D reconstruction from a computed tomography angiogram of the neck vessels demonstrated a right internal carotid artery (ICA) pseudo-aneurysm. Selective endovascular occlusion of the aneurysm was planned. However, the patient had a recurrence of severe hemoptysis during coiling. A selective right ICA injection showed an extravascular jet of contrast medium filling the pharynx. Occlusion of the ICA and the pseudo-aneurysm (trapping) was performed as quickly as possible successfully staunching the bleed. Selective left ICA injection confirmed occlusion of the right ICA and satisfactory cross filling through the anterior communicating artery. The woman was discharged and the hemoptysis never recurred.

Introduction

Hemoptysis is defined as the spitting of blood derived from the lungs or bronchial tubes as a result of pulmonary or bronchial hemorrhage.¹ It is classified as non-massive or massive on the volume of blood loss, even if there is no uniform definition for this distinction. Blood loss volume is more useful in directing action than in obtaining a diagnosis; the urgency of hemoptysis is determined from the respiratory system

compromise with hemodynamic instability rather than the amount of blood coughed up.²

The first step in making a diagnosis is to differentiate hemoptysis from hematemesis (the spitting of blood from esophagus or stomach). The second step is to understand the underlying etiologies of the hemoptysis. It varies according to the geography and demography of the population.³ Tuberculosis continues to be the most common cause of hemoptysis worldwide. Other common causes are lung cancer, pneumonia, acute and chronic bronchitis. In the differential diagnosis, there are also bronchiectasis, broncholithiasis, airway trauma or lung contusion, autoimmune condition (Wegener's granulomatosis, Goodpasture's syndrome, lupus pneumonitis), vascular source (arteriovenous malformation, pulmonary embolism, elevated pulmonary venous pressure, thoracic aortic aneurysm) or miscellaneous causes (systemic coagulopathy or use of anticoagulants or thrombolytic agents). In 7 to 34% of patients, no identifiable cause is found: these patients may warrant close monitoring and, above all, smokers older than 40 years for an increased risk of lung cancer.⁴

After a careful patient history and physical examination, a chest radiograph should be obtained. If the diagnosis remains unclear, a chest computed tomography (CT) and/or direct visualization with bronchoscopy is indicated.²

The overall goals of management are to stop the bleeding, to prevent aspiration, and to treat the underlying causes. The mortality rate depends on the bleeding rate and etiology. In the presence of massive hemoptysis (greater than 1000 mL per 24 h, or any amount of hemoptysis that compromises the patient's respiratory status) and malignancy, the mortality is about 80%.⁵ Massive hemoptysis should be considered a medical emergency, warrants an aggressive approach and emergent consultation with other specialists (pulmonologist,

Correspondence: Silvia Maestroni, Papa Giovanni XXIII Hospital, piazza OPMS 1, 24127 Bergamo, Italy.
Tel.: +39.0352673456 - Fax: +39.0352674964.
E-mail: smaestroni@asst-pg23.it

Key words: Hemoptysis; carotid aneurysm; esophageal cancer.

Contributions: the authors contributed equally.

Conflict of interest: the authors declare no potential conflict of interest.

Conference presentation: oral communication presented at the meeting *Quadrangolare di neuroradiologia interventistica Italia-Regno Unito*, 4-5 Feb 2016, Papa Giovanni XXIII Hospital, Bergamo, Italy.

Received for publication: 24 April 2016.

Revision received: 15 June 2016.

Accepted for publication: 22 June 2016.

This work is licensed under a Creative Commons Attribution NonCommercial 4.0 License (CC BY-NC 4.0).

©Copyright S. Maestroni et al., 2017

Licensee PAGEPress, Italy

Italian Journal of Medicine 2017; 11:71-74

doi:10.4081/ijm.2016.738

thoracic surgeons, interventional radiologist). Approximately 400 mL of blood within the alveolar space is sufficient to impair oxygen transfer and cause asphyxiation because it exceeds physiologic dead space.²

In case of massive or life-threatening hemoptysis, diagnosis and therapy must occur simultaneously.

We describe an unusual cause of massive hemoptysis occurred in our Unit.

Case Report

A.R. is a woman hospitalized in November 2014 in our Unit of Internal Medicine with recurrent episodes of hemoptysis.

At admission the patient was conscious and oriented; she had dry cough sometimes before hemoptysis. There was no breathing difficulty, no dyspnea, chest pain, wheeze or fever and the hemodynamic was stable. She had a past history of cervical esophageal cancer with regional lymph nodes metastases in regular oncological follow up. In 2010 she had been treated with surgery plus radio-chemotherapy. In 2011 she had a lymph nodes relapse with the necessity of a new surgery and Cyber-knife treatment. In 2013 she positioned a percutaneous endoscopic gastrostomy for dysphagia, since her performance status was very good and in 2014 she had Gamma Knife radiosurgery for cerebellar metastases. In the following months, the patient maintained the gastrostomy for feeding. She had a good quality of life, without neurological symptoms and a good performance status.

In Oct 2014, one month before our hospitalization, she was admitted to Hospital, in Pulmonology, for massive hemoptysis. She underwent esophagogastroduodenoscopy and bronchoscopy, but no lesions were detected. The chest CT identified pneumonia in right lung lobe basal, so the diagnosis was hemoptysis due to pneumonia. She was treated with antibiotic and discharged. On 5th of Nov 2014 her oncologist proposed a CT of the neck that documented actinic and surgery outcomes in right lateral cervical site, with hypodense tissue extended to hyoid bone, to submandibular and parotid space and to right lateral wall of oropharynx. The tissue goes to the skull base and incorporates the internal right carotid. A cerebral magnetic resonance confirmed this finding.

When A.R. was admitted to our division, we first suspected that the cause of recurrent hemoptysis was a possible neoplastic lung lesions or a bronchial lesion or another pneumonia or a thromboembolism. A chest CT with contrast medium showed only a centrilobular bronchiectasis and emphysema prevalent to superior lobe. Three days after admission, the patient had abundant hemoptysis, approximately one cup of blood, with abundant dark clots. The hemoglobin value went from 10 g/dL to 8.9 g/dL. Urgent endoscopies identified areas

of recent bleeding in the right pharynx and a big clot in cervical esophagus. The CT angiogram of neck vessels, instead, documented a pseudoaneurysm with a sac of 1 cm in the right ICA (Figure 1). After a neuroradiologic consulting, a selective endovascular occlusion of the aneurysm was planned. The patient underwent the procedure 3 days after. During the procedure (3 spirals were inserted in the vessel) a sudden recurrence of severe hemoptysis occurred during coiling, due to the rupture of the carotid wall that was very fragile and thin. The right ICA injection showed an extravascular jet of contrast medium filling the pharynx (Figure 2). Other 17 spirals were quickly released in ICA causing complete occlusion of right ICA. Occlusion of the ICA and the pseudoaneurysm (trapping) was performed as quickly as possible successfully staunching the bleed (Figure 3). At this point, the problem was the neurological outcome of the patient due to the complete carotid occlusion. To verify the cerebral circulation, the neuroradiologist performed a selective left ICA injection that confirmed occlusion of the right ICA and satisfactory cross-filling through the anterior communicating artery (Figure 4). The left vertebral injection documented instead a good filling of right media cerebral artery through the posterior communicating artery. Fortunately, our woman had no neurological outcomes and she had no more hemoptysis. She was discharged in good conditions and good performing status. No other active therapies for her cancer were done. Her conditions remained stable and acceptable, with no recurrence of hemoptysis; after several months she gradually deteriorated and she died 1 year after for neoplastic cachexia.

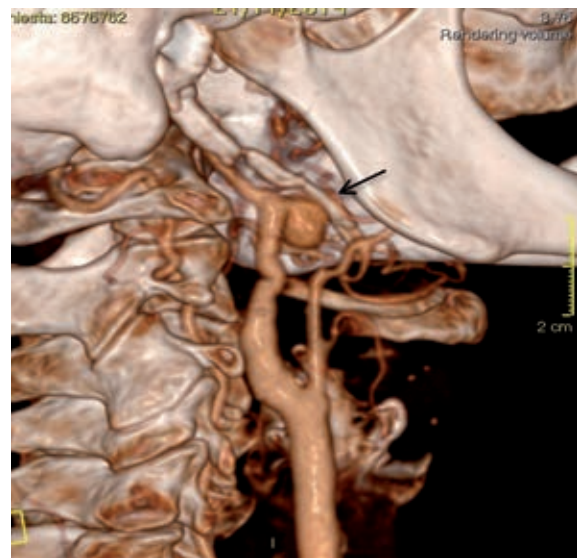


Figure 1. 3D reconstruction from a computed tomographic angiogram of neck with the pseudoaneurysm of internal right carotid (black arrow).

Discussion and Conclusions

The transient rupture in oropharynx of a pseudoaneurysm of internal carotid is a very unusual cause of hemoptysis. In this case its development was due to the neoplastic relapse and the radiotherapy involving

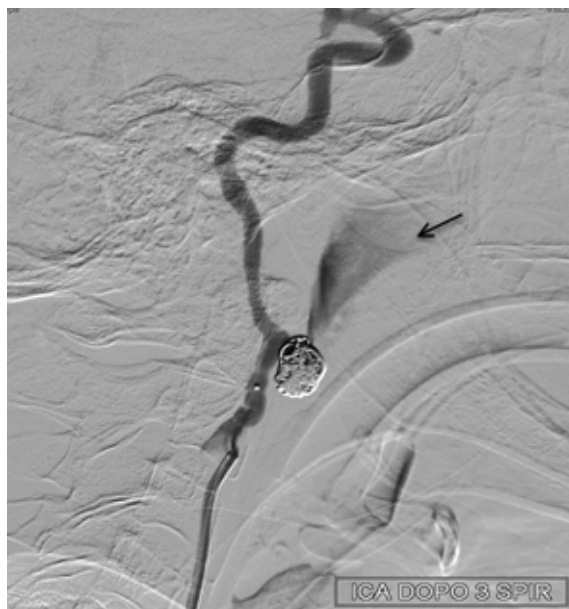

Figure 2. The angiographic image of the extravascular jet of contrast medium filling the pharynx (black arrow).

the carotid. The interventional radiologist decided to occlude first the pseudo-aneurysm, but on hindsight the best choice would have been to occlude immediately the entire IC to prevent its rupture. The wall of the pseudo-aneurysm was in fact very fragile and thin because of infiltration of cancer, history of radiotherapy and surgery, so during the interventional procedure on the pseudo-aneurysm the rupture of the wall occurred. This dramatic condition is called *carotid blowout syndrome* (CBS). It is a life-threatening complication of head and neck cancer. It usually occurs as a post-operative complication or when the tumor compromises the vascular axis. The presence of ulceration and lymph node irradiation are risk factors of CBS. One of the various methods used for emergency management of CBS is graft-stent placement,⁶ but short-term complications include rebleeding, while long term complications include in-stent thrombosis and abscess formation.⁷

Our interventional radiologist decided to go on with spirals and the trapping was performed as quickly as possible successfully staunching the bleed. In our case the life expectancy based on the original pathology was good (>6 months) and we decided not to let the patient die on the table and do whatever was in our capabilities to save her life. In the end this strategy appeared to be appropriate in our case because the patient was discharged in good condition and without neurological disability. She gained 1 year of independent life, without other episodes of hemoptysis, dying at the end for neoplastic cachexia.

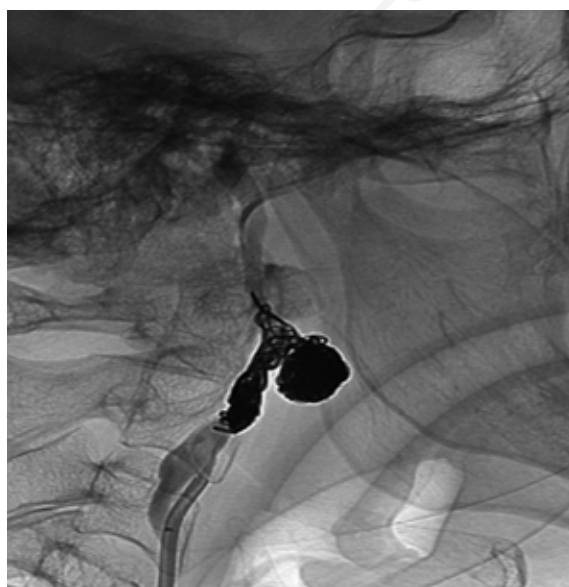


Figure 3. The right internal carotid artery after the complete occlusion with the spirals.

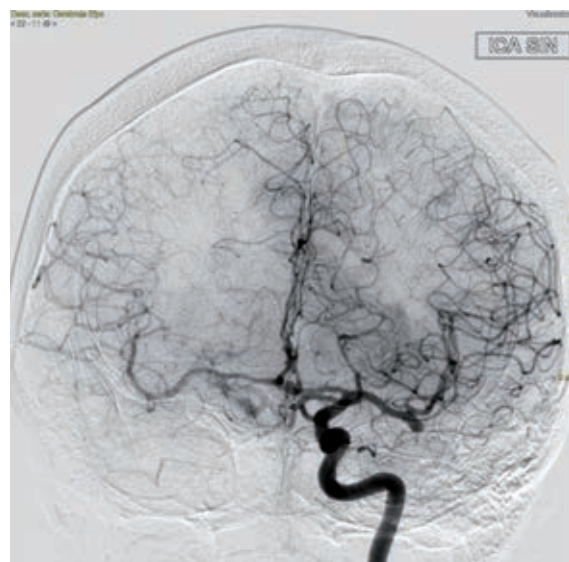


Figure 4. The cerebral circle after the procedure of right internal carotid occlusion: it showed satisfactory cross-filling through the anterior communicating artery.

References

1. Stedman TL. Stedman's medical dictionary. 27th ed. Philadelphia, PA: Lippincott Williams & Wilkins; 2000.
2. Mandell LA, Wunderink RG, Anzueto A, et al. Infectious Diseases Society of America/American Thoracic Society consensus guidelines on the management of community-acquired pneumonia in adults. *CID* 2007;44:S27-72.
3. Abal AT, Nair PC, Cherian J. Hemoptysis: etiology, evaluation, and outcome-a prospective study in a third-world country. *Respire Med* 2001;95:548-52.
4. Herth F, Ernst A, Becker HD. Long-term outcome and lung cancer incidence in patients with hemoptysis of unknown origin. *Chest* 2001;120:1592-94.
5. Jean-Baptiste E. Clinical assessment and management of massive hemoptysis. *Crit Care Med* 2000;28:1642-47.
6. Yamazaki H, Ogita M, Himei K, et al. Carotid blowout syndrome in pharyngeal cancer patients treated by hypofractionated stereotactic re-irradiation using CyberKnife: a multi-institutional matched-cohort analysis. *Radiother Oncol* 2015;115:67-71.
7. Wu CJ, Lin WC, Hsu JS, et al. Follow-up for covered stent treatment of carotid blow-out syndrome in patients with head and neck cancer. *Br J Radiol* 2016;89: 20150136.

Non-commercial use only