

Clinical case and short review of extreme short bowel syndrome: an update 21 years after

Pasquale Mansueto,¹ Aurelio Seidita,¹ Salvatore Iacono,¹ Antonio Carroccio^{1,2}

¹Internal Medicine, University Hospital of Palermo; ²Internal Medicine, Sciacca Hospital, Agrigento, Italy

ABSTRACT

Short bowel syndrome refers to the malabsorptive state caused by loss of significant portions of the small intestine, whose clinical framework is characterized by malnutrition, diarrhea, dehydration, weight loss, and low-weight-related symptoms/signs. These clinical conditions seem to be related to the length of resection. Twenty-one years ago we reported the clinical case of an infant, who underwent a massive resection of the loops of the small intestine, of the cecum and of part of the ascending colon, due to intestinal malrotation with volvulus. The residual small intestine measured just 11 cm and consisted of the duodenum and a small part of jejunum, in the absence of the ileocecal valve, configuring the case of a *ultra-short bowel syndrome*. In this report, we update the case, reporting the patient succeeded to obtain a good weight gain and to conduct a quite normal lifestyle, despite the long-term consequences of such resection.

Introduction

Short bowel syndrome (SBS) refers to the malabsorptive state caused by loss of significant portions of the small intestine. The clinical impact of SBS is far-reaching because extensive resections can lead to malabsorption of macronutrients, micronutrients, electrolytes, and water, resulting in malnutrition, diarrhea, dehydration, weight loss, and to malnutrition- and low-weight-related symptoms/signs (*i.e.*, confu-

sion, weakness, impaired growth and sexual development, and premature ageing). In addition, resection of the ileocecal valve may lead to bacterial contamination and growth of residual intestine, and to small intestinal bacterial overgrowth (SIBO) syndrome¹⁻⁵ (Figure 1). In general, to obtain a favorable outcome in the absence of the ileocecal valve, a minimum of 25 cm of residual small intestine length, is required.⁶

Twenty-one years ago we reported the clinical case of an infant, who underwent massive resection of the loops of the small intestine, of the cecum and of part of the ascending colon, due to intestinal malrotation with volvulus. The residual small intestine measured just 11 cm and consisted of the duodenum and a small part of jejunum, in the absence of the ileocecal valve. As a result of the demolitive extent of surgery, the young patient developed a rare *ultra-short bowel syndrome*, which led to the subsequent need of parental nutrition (PN) for almost one year. His successive clinical course was characterised by various complications, *i.e.*, metabolic acidosis, and infections.⁷

In this report, we update the case, reporting the patient succeeded to obtain a good weight gain and to conduct a quite normal lifestyle, despite the long-term consequences of such resection, including an oxalate-related nephrocalcinosis and ureteral lithiasis, leading to chronic renal failure and hydronephrosis.

Case Report

This male infant was born in March 1988, his weight esteemed of 3.450 g. Four days after the child-birth, the patient experienced persistent vomiting, provoked by an intestinal malrotation (a familiar condition, of which both the mother and the sister suf-

Correspondence: Pasquale Mansueto, Internal Medicine, University Hospital of Palermo, via del Vespro 129, 90127 Palermo, Italy.
Tel.: +39.091.6554347 - Fax: +39.091.6554347.
E-mail: pasquale.mansueto@unipa.it

Key words: Ultra-short bowel syndrome; malabsorption; malnutrition; small intestinal bacterial overgrowth.

Contributions: PM studied the case, reviewed literature and wrote the paper; AS, SI, studied the case and reviewed literature; AC, coordinated the study group, reviewed literature and wrote the paper.

Conflict of interest: the authors declare no potential conflict of interest.

Received for publication: 12 September 2014.
Revision received: 30 March 2015.
Accepted for publication: 22 April 2015.

This work is licensed under a Creative Commons Attribution NonCommercial 4.0 License (CC BY-NC 4.0).

©Copyright P. Mansueto et al., 2016
Licensee PAGEPress, Italy
Italian Journal of Medicine 2016; 10:45-51
doi:10.4081/ijm.2016.543

ferred from) with volvulus; for this, he underwent massive resection of the loops of the small intestine, of the cecum and of part of the ascending colon. The residual small intestine measured just 11 cm and consisted of the duodenum and a small part of jejunum in the absence of the ileocecal valve. As a direct consequence of the demolitive extent of surgery, the newborn was fed with PN (glucose solution *plus* solutions of amino acids, lipids, electrolytes, oligoelements and vitamins), with a caloric content of 150 cal/kg body weight, using a central venous catheter positioned in the superior vena cava. The patient continued PN for about 4 months when it was associated with a semi-elemental formula consisting of hydrolized protein and medium chain triglycerides and, at the age of six months, ground rice cream and lyophilized meat were associated too. The routine blood chemistry and nutritional parameters (hemoglobin, albumin and triglycerides) were satisfactory, even if the child grew slowly than the average for his age and showed steatorrhea. When he was 8 months old, due to an episode of septicemia after catheter infection (*Staphylococcus aureus* was isolated both from catheter itself and from blood culture), PN was suspended, catheter removed and oral diet was continued with rice cream, and lyophilized meat, together with human breast milk provided by a sister, who recently given birth, until the twelfth month, since no other wet nurse was available, achieving a weight of about 9 kg when he was 12 months old. PN was subsequently reinstated in as-

sociation with the oral diet. Blood chemistry was normal, but steatorrhea persisted. At 15 months, a radiograph of the digestive system showed an apparent modest lengthening (20 cm) of the residual loop of the duodenum and a considerable lengthening of the colon. PN was discontinued. On the twentieth month, the sudden onset of fecal vomiting, related to a probable bacterial contamination, due to the absence of ileocecal valve, in association with diarrhea, metabolic acidosis with normal anion gap [13 mEq/L, range values (r.v.) 8-16 mEq/L] (with onset of severe mental confusion, till coma) and weight loss, forced hospitalization. During hospital stay, he was treated with intramuscular gentamicin, oral metronidazole, and intravenous bicarbonate, for ten days, with complete resolution of the above-mentioned symptoms. Further hospitalizations occurred during the 22nd and 23rd month for the same reason (diarrhea and metabolic acidosis with normal anion gap) and the patient was treated again with intravenous bicarbonate to control the persistent state of acidemia. During the last hospital stay, *Klebsiella spp.* sensitive to aminoglycoside was isolated from a duodenal probe, so a prolonged treatment with neomycin and loperamide (this last one never suspended, see below, *Discussion* section) was started, together with the transient reinsertion of PN. These therapies led to an improvement of patient's clinical condition, which allowed physicians to discontinue PN. In the subsequent years, further episodes of diarrhea and metabolic acidosis with normal anion

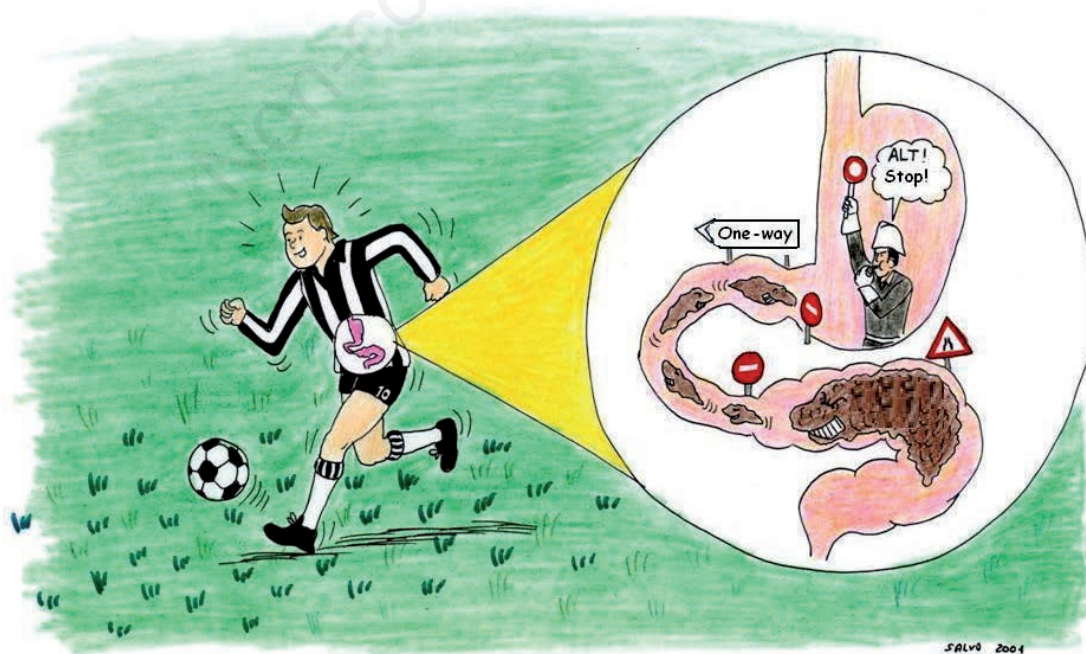


Figure 1. Bacterial backscatter and colonization in patients with extreme short bowel syndrome.

gap, often related to an excessive carbohydrates intake (bread and pasta), occurred, being always successfully treated with antimicrobial therapy, intravenous bicarbonate, and restriction of carbohydrates. All these episodes were characterized by serum lactate values within normal limits, low fecal pH and positive +++ fecal clintest (to determine the amount of reducing substances, generally glucose).

From January to November 1991, the patient received human milk from a wet nurse, to exclude all other types of milk.

In early adolescence, beginning to practice amateur sports, further admissions were necessary. In fact, already under mild to moderate physical stress, few episodes of fecal vomiting, with pH reduction and metabolic acidosis with normal anion gap, occurred. Even in such cases, appropriate correction of acid-base imbalances were performed *via* bicarbonate infusion therapy (20-30 mEq/day) within 2-4 days.

At the age of sixteen, probably as a result of acute diarrhea with intense dehydration, he was admitted to a Department of Nephrology, suffering from acute renal failure, promptly treated with intravenous hydration, with a subsequent rapid improvement of renal function.

Two years later, in March 2006, he underwent intestinal X-ray with barium meal that showed the residual small bowel loops (40 cm in length) placed in the right abdominal quadrants and the colon in the left ones.

In June 2009, he was readmitted to Department of Nephrology due to a severe episode of metabolic aci-

dosis with normal anion gap. Here he was diagnosed with mild chronic kidney disease (CKD) secondary to bilateral nephrocalcinosis. Subsequently, in October 2012, onset of acute renal failure, due to a bilateral III grade hydronephrosis, secondary to a distal ureteral lithiasis, forced the placement of a bilateral ureteral stenting.

In April 2013 the patient was admitted to our Department of Internal Medicine for a clinical re-evaluation. He was in mediocre clinical conditions, weight 61.5 kg, height 171 cm, body mass index (BMI) 21, muscle masses and fat well represented. Blood chemistry and urinalysis showed low levels of cholesterol and triglycerides, a modest increase in serum pancreatic enzymes and a CKD with an estimated glomerular filtration rate (by Chronic Kidney Disease Epidemiology Collaboration, CKD-EPI) of 39.7 mL/min/1.73 m² and proteinuria (Tables 1 and 2). An assessment of phospho-calcic metabolism and thyroid function was performed: thyroid hormones, thyroid-stimulating hormone, serum parathormone, vitamin D, osteocalcin, C-terminal telopeptide, bone-specific alkaline phosphatase, and serum folate were normal; serum and urinary calcium were within normal range [9.1 mg/dL (r.v. 8.4-10.2 mg/dL) and 163 mg/24 h (r.v. 100-300), respectively], whereas serum and urinary phosphate were higher [4.3 mg/dL (r.v. 2.7-4.5 mg/dL) and 1650 mg/24 h (r.v. 400-1300), respectively]. Vitamin B12 was 2001 pg/mL (r.v. 197-890), because the patient was under chronic bimestrial intramuscular therapy with vitamin

Table 1. Patient's blood chemistry on April 2014.

Hemoglobin	15.3 g/dL (r.v. 12-18 g/dL)
Mean corpuscular volume	101.8 fL (r.v. 80-99 fL)
Mean corpuscular hemoglobin	34.2 pg (r.v. 26-32 pg)
Total cholesterol	77 mg/dL (r.v. 0-200 mg/dL)
High-density lipoproteins-cholesterol	27 mg/dL (r.v. >55 mg/dL)
Triglycerides	58 mg/dL (r.v. 0-200 mg/dL)
Amylase	171 U/L (r.v. 28-100 U/L)
Lipase	106 U/L (r.v. 13-60 U/L)
Immunoglobulin M	24 mg/dL (r.v. 40-230 mg/dL)
Albumin	4.8 g/dL (r.v. 3.4-4.8 g/dL)
Sodium	142 mEq/L (r.v. 136-145 mEq/L)
Potassium	5.7 mEq/L (r.v. 3.5-5.1 mEq/L)
Magnesium	1.7 mg/dL (r.v. 1.5-2.5 mg/dL)
Total serum calcium	10 mg/dL (r.v. 8.4-10.2 mg/dL)
Uric acid	8.5 mg/dL (r.v. 3.4-7 mg/dL)
Urea	48 mg/dL (r.v. 10-50 mg/dL)
Creatinine	2.3 mg/dL (r.v. 0.6-1.1 mg/dL)

r.v., range values.

B12 and folates, to correct potential onset of megaloblastic anemia due to last ileal loop resection. The arterial blood gas analysis and the acid-base balance showed a slight metabolic acidosis (pH 7.32, bicarbonate 18 mmol/L, normal lactacidemia and normal anion gap). Abdominal ultrasonography showed *kidneys volume reduction (transverse diameter max 6 cm), with preserved echogenicity but with numerous bilateral lithiasic formation in all the renal calyces (the largest 1 cm), without images referable to hydronephrosis. Normal pancreatic region.* Ultrasonographic study of the intestinal loops showed *an ectasic loop into the right quadrants of about 4 cm of diameter, containing liquid and corpusculated material, with increased peristalsis (washing machine sign), some lymph nodes with diameter between 1 and 2 cm, and thickening of some bowel loops up to 8 mm, with preserved stratification.* Lumbar and femoral bone densitometry by dual-energy X-ray absorptiometry was normal. The patient refused to undergo capsule endoscopy. Therefore, it was increased oral bicarbonate administration just practiced at home to better correct metabolic acidosis. An angiotensin II receptor blocker was introduced to reduce proteinuria. Given the high levels of uric acid, allopurinol was introduced too. The patient was discharged in good clinical condition, under continuous treatment with sodium bicarbonate [500 mg *per os* (po), every 24 h, q24h], antimicrobial drugs (trimethoprim/sulfamethoxazol, or cotrimoxazole, 160 mg/800 mg po, twice a day, chosen based both on the previous well tolerance and positive effect on bowel habits of the patient and to treat urinary infection), administered in alternating cycles, probiotics (2 thousand million spores of multiantibiotic-resistant *Bacillus clausii*, po, q24h), vitamin B12 (1000 mcg intramuscular, q24h) and folate (15 mg po, q24h), lop-

eramide (25 mg po, q24h), olmesartan (10 mg po, q24h), and allopurinol (150 mg po, q24h). The patient is still in outpatient follow-up at our Department.

Discussion

Three types of intestinal resection may lead to SBS. In patients, like the ours, with jejunocolic anastomosis, all or most of the ileum is removed, together with the ileocecal valve, with at least part of the colon remaining. In contrast, patients with an end-jejunos-tomy retain some jejunum, but the ileum and colon are completely removed, and the jejunum forms the end of the intestines. The third type of intestinal resection is the jejunoleal anastomosis, predominantly a jejunal resection, leaving ≥ 10 cm of terminal ileum remaining and the entire colon intact.

Patient outcomes are typically better for: i) greater length of remnant bowel. Patients retaining less than one-third of the jejunoleal segment (≤ 200 cm) typically experience symptoms of SBS. Patients without functional colon whose remnant small intestinal length is < 100 cm, and patients with a functional colon and < 60 cm of small intestine remaining will usually be dependent on parenteral nutrition and/or intravenous fluid; ii) jejunal, as opposed to ileal, resections; in fact, the ileum adapts structurally and functionally, whereas the jejunum can adapt only functionally; iii) ileocecal valve sparing; in fact, the valve is an important regulator of intestinal transit speed and a physical barrier to antero-grade flow of chyme from the large to small intestine.⁸⁻¹¹

Our patient did not have any of the above conditions accepted as being favorable to survival: in fact, the infant's residual small intestine was < 25 cm (only

Table 2. Patient's urinalysis on April 2014.

pH	5.5 (r.v. 5.5-7)
Glucose	0 mg/dL (r.v. absence)
Proteinuria	142.36 mg/dL (r.v. 0-15) 4270.8 mg/24 h (r.v. 0-140)
Albuminuria	957.8 mg/L (r.v. 0-20) 2873.4 mg/24 h (r.v. 0-30)
Hemoglobin	1 mg/dL (r.v. absence)
Urobilinogen	0.2 mg/dL (r.v. 0-1 mg/dL)
Nitrites	Absence (r.v. absence)
Leukocyte esterase	500 Leu/ μ L (r.v. absence)
Epithelial cells	20 n/ μ L (r.v. 0-20 n/ μ L)
Red blood cells	11,838 n/ μ L (r.v. 0-15 n/ μ L)
White blood cells	420 n/ μ L (r.v. 0-18 n/ μ L)
Bacteria	896 n/ μ L (r.v. 0-4000 n/ μ L)
Microscopic examination of the urine sediment	Numerous calcium oxalate crystals

r.v., range values.

11 cm), no segment of the ileum remained, surgery included resection of part of the colon, and, finally, the ileocecal valve was not spared. Therefore the reported case is certainly of great interest in view of the patient's capacity to survive for many years after massive resection of the small intestine, despite several associated negative prognostic factors.^{12,13} To our knowledge, previously studies have already reported cases of subjects with residual intestines of lengths ranging from 11 to 13 cm. who survived in good clinical condition, but in all these cases the ileocecal valve had been spared, and PN support could not be eliminated in most cases.^{6,14-17}

The main factor that could explain such a successful recovery may have been, in our hypothesis, the protracted breast-feeding. Human milk plays a very positive influence on cell proliferation and on adaptive transformation of the residual intestine. Factors that could affect this specific feature of human milk could be both the hormone content and the presence of epidermal growth factor as well as other growth factors that are as yet not completely understood.¹⁸⁻²⁴ Anyway, it still remains to be determined whether these adaptations are limited to mucosal hyperplasia or lead to an actual lengthening of the residual intestine.²⁵⁻²⁷ The radiographic studies we performed sixteen years after intestine resection proved a lengthening of the residual small intestine, 40 cm long, but, unfortunately, the patient refused to undergo a capsule endoscopy, a possibility to obtain a direct evidence of the mucosal morphology. However, the absorption capacity of the patient's intestine is once more satisfactory, as shown by its height-weight growth, its current BMI, and some of the nutritional hematochemical parameters (hemoglobin and serum albumin).

It is also important to highlight the constant *acidemic environment* of our patient, with recurrent exacerbations of non D-lactic metabolic acidosis, which represented the most serious clinical problem. This sub-continuous acidosis state, with onset of severe confusion, till coma, forcing several hospitalizations, to correct, via intravenous administration of large amount of bicarbonate, the acid-base imbalance, could be explained by the massive formation and absorption of organic and volatile fatty acids, due to bacterial colonization of the short tract of residual intestine, favored by the absence of the ileocecal valve. This condition was worsened by a moderate physical activity.²⁸⁻³⁴ The main features of the patient's metabolic acidosis, resulting from this process, recall the findings of monosaccharide intolerance (normal lactacidemia, normal anion gap, low fecal pH, fecal clintest +++). This aspect is further confirmed by temporal link between these attacks and an excessive carbohydrates intake, which confirms the role played by monosaccharides in causing these symptoms. It is

therefore understandable that a low-carbohydrates diet lowers the risk of acidosis, as has been the case over the past years with our patient, who more carefully followed the diet we prescribed.³⁵⁻³⁹

Furthermore, uninterrupted antibiotic treatment (cotrimoxazole), administered in alternating cycles, together with probiotic administration, has certainly reduced intestinal pathogen bacterial contamination and growth, therefore reducing the risk of developing the SIBO syndrome, and, to date, there have been no side-effects, nor has the treatment promoted the growth of lactobacilli leading to lactic acidosis, as it has been previously hypothesized.⁴⁰⁻⁴²

However, a continuous assumption of oral bicarbonate is still needed and the quite frequent episodes of severe acidosis require an extremely large amount of intravenous bicarbonate.

Other possible key point, allowing the good success of massive intestine resection and long-term survival of our patient, could be the chronic replacement therapy with intramuscular vitamin B12 and folates. It has been reported that extended resection of small intestine, particularly the ones involving the last ileal loop, may determine a vitamin B12 absorption deficit and a consequential megaloblastic anemia.⁴³⁻⁴⁵ As well, the prolonged use of loperamide, to reduce the speed of intestinal transit and, therefore, to increase the absorption capacity of the residual loops, should not be underestimated.^{43,46,47}

Finally, it is noteworthy the development, after 21 years, of an oxalate-related bilateral nephrocalcinosis, a condition, which led to CKD, successively worsened by several episodes of ureteral lithiasis, up to the development of a III degree hydronephrosis which required the placement of bilateral ureteral stents. As regards its pathogenesis, we recall that dietary oxalate physiologically complexes with enteric calcium to form an insoluble salt, so that only less than 10% of oxalate is absorbed. Extensive small intestinal resection causes fats and bile salts malabsorption, inhibiting these last ones to bind enteric calcium, therefore, increasing free oxalate and enhancing colonic permeability, which lead to *enteric* hyperoxaluria.⁴⁸⁻⁵¹ Other coexisting metabolic abnormalities in the SBS, including volume depletion, chronic metabolic acidosis, hypocitraturia and hypomagnesaemia with hypomagnesiuria, could predispose to progressive nephrocalcinosis and recurrent urolithiasis.⁵² To date, the patient presents a moderate reduction of glomerular filtrate rate (III stage National Kidney Foundation, NKF), associated with the recent appearance of mild proteinuria. For this reason, an angiotensin II receptor blocker (*i.e.*, olmesartan) was introduced, thanks to its well-known effect on reducing systemic blood pressure, intraglomerular pressure, proteinuria, and directly acting on glomerular podocytes.⁵³

In conclusion, the case we described and updated after 20 years shows that, despite the massive resection of small intestine, involving ileocecal valve, and a part of the colon, and several associated negative prognostic factors, it is possible to survive, and even achieve full independence from PN support. We also underlined that the main problems onset during these years were the persistence of metabolic acidosis and the onset of bilateral nephrocalcinosis and CKD, due to enteric hyperoxaluria.

We still do not know what factors, apart from prolonged breast-feeding and long-time use of sodium bicarbonate, cotrimoxazole, probiotics, vitamin B12 and folate, and loperamide, may have led to such an exceptional result, but this case clearly shows that the currently accepted guidelines in the literature concerning the limits of intestinal resection compatible with survival probably should be reviewed.

References

1. Storch KJ. Overview of short bowel syndrome: clinical features, pathophysiology, impact, and management. *JPEN J Parenter Enteral Nutr* 2014;38:5S-7S.
2. Kalaitzakis E, Carlsson E, Josefsson A, Bosaeus I. Quality of life in shortbowel syndrome: impact of fatigue and gastrointestinal symptoms. *Scand J Gastroenterol* 2008; 43:1057-65.
3. Misiakos EP, Macheras A, Kapetanakis T, Liakakos T. Short bowel syndrome: current medical and surgical trends. *J Clin Gastroenterol* 2007;41:5-18.
4. Shanbhogue LK, Molenaar JC. Short bowel syndrome: metabolic and surgical management. *Br J Surg* 1994;81:486-99.
5. Van Gossum A, Cabre E, Hébuterne X, et al. ESPEN Guidelines on parenteral nutrition: gastroenterology. *Clin Nutr* 2009;28:415-27.
6. Dorney SF, Ament ME, Berquist WE, et al. Improved survival in very short small bowel of infancy with use of long-term parenteral nutrition. *J Pediatr* 1985;107: 521-5.
7. Iacono G, Carroccio A, Montalto G, et al. Extreme short bowel syndrome: a case for reviewing the guidelines for predicting survival. *J Pediatr Gastroenterol Nutr* 1993; 16:216-9.
8. Buchman AL, Scolapio J, Fryer J. AGA technical review on short bowel syndrome and intestinal transplantation. *Gastroenterology* 2003;124:1111-34.
9. Sundaram A, Koutkia P, Apovian CM. Nutritional management of short bowel syndrome in adults. *J Clin Gastroenterol* 2002;34:207-20.
10. Wilmore DW, Byrne TA, Persinger RL. Short bowel syndrome: new therapeutic approaches. *Curr Probl Surg* 1997;34:389-444.
11. DiBaise JK. Management of the short bowel syndrome. In: DeLegge MH, ed. *Nutrition and Gastrointestinal Disease*. Totowa, NJ: Humana Press; 2007. pp 177-204.
12. Wall EA. An overview of short bowel syndrome management: adherence, adaptation, and practical recommendations. *J Acad Nutr Diet* 2013;113:1200-8.
13. Amin SC, Pappas C, Iyengar H, et al. Short bowel syndrome in the NICU. *Clin Perinatol* 2013;40:53-68.
14. Diamanti A, Conforti A, Panetta F, et al. Long-term outcome of home parenteral nutrition in patients with ultra-short bowel syndrome. *J Pediatr Gastroenterol Nutr* 2014;58:438-42.
15. Holt D, Easa D, Shim W, Suzuki M. Survival after massive small intestinal resection in a neonate. *Am J Dis Child* 1982;136:79-80.
16. Postuma R, Moroz S, Friesen F. Extreme short-bowel syndrome in an infant. *J Pediatr Surg* 1983;18:264-8.
17. Kurz R, Sauer H. Treatment and metabolic findings in extreme short-bowel syndrome with 11 cm jejunal remnant. *J Pediatr Surg* 1983;18:257-63.
18. Corps AN, Brown KD. Stimulation of intestinal epithelial cell proliferation in culture by growth factors in human and ruminant mammary secretions. *J Endocrinol* 1987;113:285-90.
19. Ichiba H, Kusuda S, Itagane Y, et al. Measurement of growth promoting activity in human milk using a fetal small intestinal cell line. *Biol Neonate* 1992;61:47-53.
20. Playford RJ, Woodman AC, Clark P, et al. Effect of luminal growth factor preservation on intestinal growth. *Lancet* 1993;341:843-8.
21. Wagner CL, Forsythe DW. Effect of human milk and recombinant EGF, TGF α , and IGF-1 on small intestinal cell proliferation. *Adv Exp Med Biol* 2000;478: 373-4.
22. Olieman JF, Tibboel D, Penning C. Growth and nutritional aspects of infantile short bowel syndrome for the past 2 decades. *J Pediatr Surg* 2008;43:2061-9.
23. Lönnnerdal B. Nutritional and physiologic significance of human milk proteins. *Am J Clin Nutr* 2003;77:1537S-43S.
24. Dvorak B. Milk epidermal growth factor and gut protection. *J Pediatr* 2010;156:S31-5.
25. Butler DB. Compensatory mechanisms following massive small bowel resection for intestinal volvulus. *Surg Gynecol Obstet* 1959;109:478-81.
26. Schefflan M, Galli SJ, Perrotto J, et al. Intestinal adaptation after extensive resection of the small intestine and prolonged administration of parenteral nutrition. *Surg Gynecol Obstet* 1976;143:757-62.
27. Thompson J, Sudan D. Intestinal lengthening for short bowel syndrome. *Adv Surg* 2008;42:49-61.
28. Gracey M. Intestinal microflora and bacterial overgrowth in early life. *J Pediatr Gastroenterol Nutr* 1982;1:13-22.
29. Buccigrossi V, Nicastro E, Guarino A. Functions of intestinal microflora in children. *Curr Opin Gastroenterol* 2013;29:31-8.
30. Guarino A, Wudy A, Basile F, et al. Composition and roles of intestinal microbiota in children. *J Matern Fetal Neonatal Med* 2012;25:63-6.
31. Cosnes J, Gendre JP, Le Quintrec Y. Role of the ileocecal valve and site of intestinal resection in malabsorption after extensive small bowel resection. *Digestion* 1978;18:329-36.
32. Imamura M, Toda M, Suzuki Y, et al. The role of humoral factors and the ileocecal valve in pathological changes occurring after distal small bowel resection. *Tohoku J Exp Med* 1987;151:155-68.
33. Weijers HA, Van De Kamer JH. Aetiology and diagno-

- sis of fermentative diarrhoeas. *Acta Paediatr* 1963;52:329-37.
34. Kien CL. Digestion, absorption, and fermentation of carbohydrates in the newborn. *Clin Perinatol* 1996;23:211-28.
 35. Bongaerts G, Bakkeren J, Severijnen R, et al. Lactobacilli and acidosis in children with short small bowel. *J Pediatr Gastroenterol Nutr* 2000;30:288-93.
 36. Ramakrishnan T, Stokes P. Beneficial effects of fasting and low carbohydrate diet in D-lactic acidosis associated with short-bowel syndrome. *JPEN J Parenter Enteral Nutr* 1985;9:361-3.
 37. Nightingale JM. Management of patients with a short bowel. *Nutrition* 1999;15:633-7.
 38. Mobarhan S. Carbohydrate versus fat in the dietary treatment of short-bowel syndrome. *Nutr Rev* 1994;52:354-6.
 39. Bongaerts GP, Severijnen RS. Arguments for a lower carbohydrate-higher fat diet in patients with a short small bowel. *Med Hypotheses* 2006;67:280-2.
 40. Perlmutter DH, Boyle JT, Campos JM, et al. D-Lactic acidosis in children: an unusual metabolic complication of small bowel resection. *J Pediatr* 1983;102:234-8.
 41. Godey F, Bouasria A, Ropert M, et al. Don't forget to test for D-lactic acid in short bowel syndrome. *Am J Gastroenterol* 2000;95:3675-7.
 42. Zhang DL, Jiang ZW, Jiang J, et al. D-lactic acidosis secondary to short bowel syndrome. *Postgrad Med J* 2003;79:110-2.
 43. Sulkowski JP, Minneci PC. Management of short bowel syndrome. *Pathophysiology* 2014;21:111-8.
 44. Valman HB, Roberts PD. Vitamin B12 absorption after resection of ileum in childhood. *Arch Dis Child* 1974;49:932-5.
 45. Kotilea K, Quennery S, Decroës V, Hermans DA. Successful sublingual cobalamin treatment in a child with short-bowel syndrome. *J Pediatr Pharmacol Ther* 2014;19:60-3.
 46. Jeejeebhoy KN. Short bowel syndrome: a nutritional and medical approach. *CMAJ* 2002;166:1297-302.
 47. Kumpf VJ. Pharmacologic management of diarrhea in patients with short bowel syndrome. *JPEN J Parenter Enteral Nutr* 2014;38:38S-44S.
 48. Chen CC, Chu P, Cheng CJ, Lin SH. Bilateral nephrocalcinosis in short bowel syndrome. *Intern Med J* 2006;36:331-2.
 49. Rahman N, Hitchcock R. Case report of paediatric oxalate urolithiasis and a review of enteric hyperoxaluria. *J Pediatr Urol* 2010;6:112-6.
 50. Sentís A, Quintana LF, Massó E, et al. Acute renal failure due to oxalate crystal deposition and enteric hyperoxaluria. *Nefrologia* 2011;31:121-3.
 51. Ceulemans LJ, Nijs Y, Nuytens F, et al. Combined kidney and intestinal transplantation in patients with enteric hyperoxaluria secondary to short bowel syndrome. *Am J Transplant* 2013;13:1910-4.
 52. Le JD, Eisner BH, Tseng TY, et al. Laterality of nephrocalcinosis in kidney stone formers with severe hypocitraturia. *BJU Int* 2011;107:106-10.
 53. Ono T, Sanai T, Miyahara Y, Noda R. Olmesartan is more effective than other angiotensin receptor antagonists in reducing proteinuria in patients with chronic kidney disease other than diabetic nephropathy. *Curr Ther Res Clin Exp* 2013;74:62-7.