

## Appendix

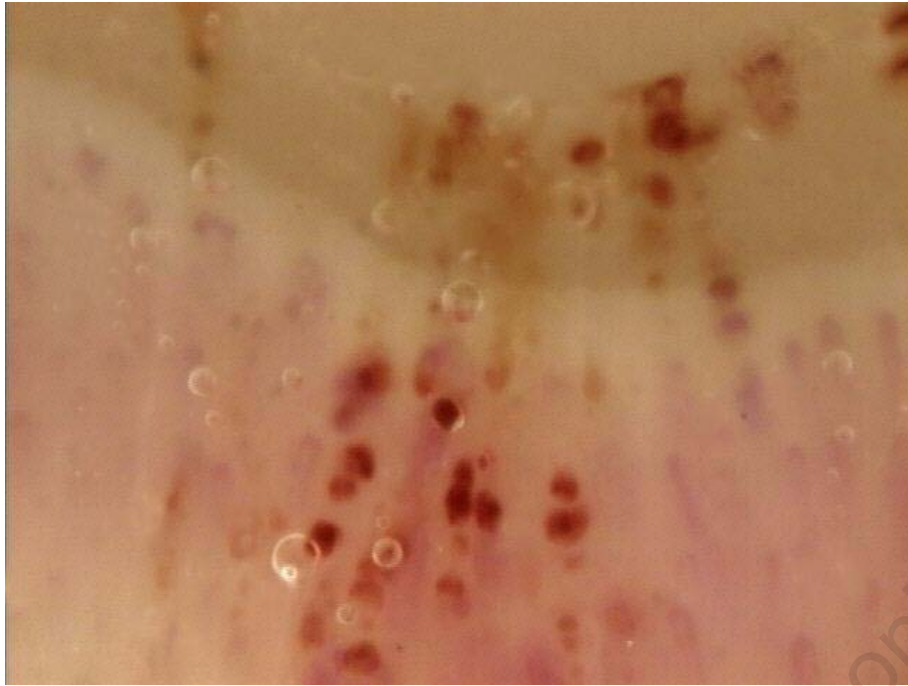
---

### **Nailfold videocapillaroscopy in internal medicine**

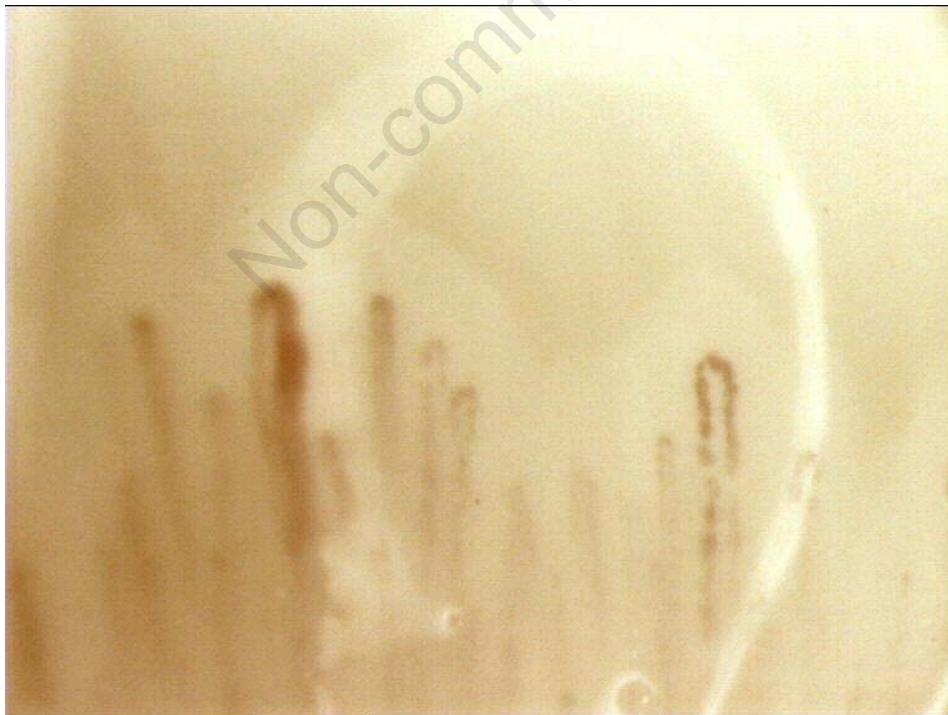Paola Faggioli, Antonio Tamburello, Alba Sciascera, Adele Giulia Gilardi, Antonino

Mazzone

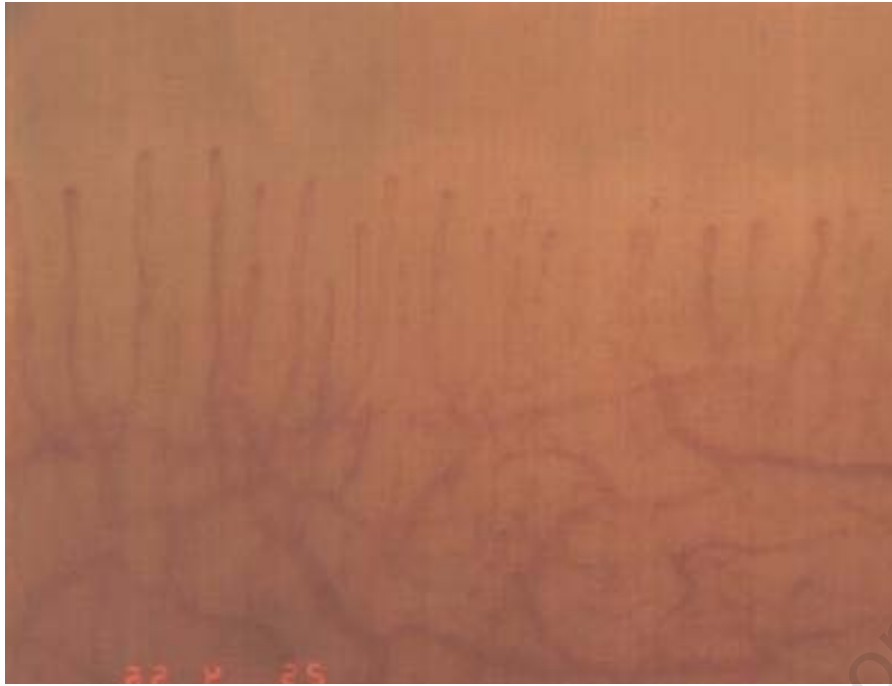---



**Figure 1. Capillaroscopic pattern in antiphospholipids syndrome phospholipids syndrome.**

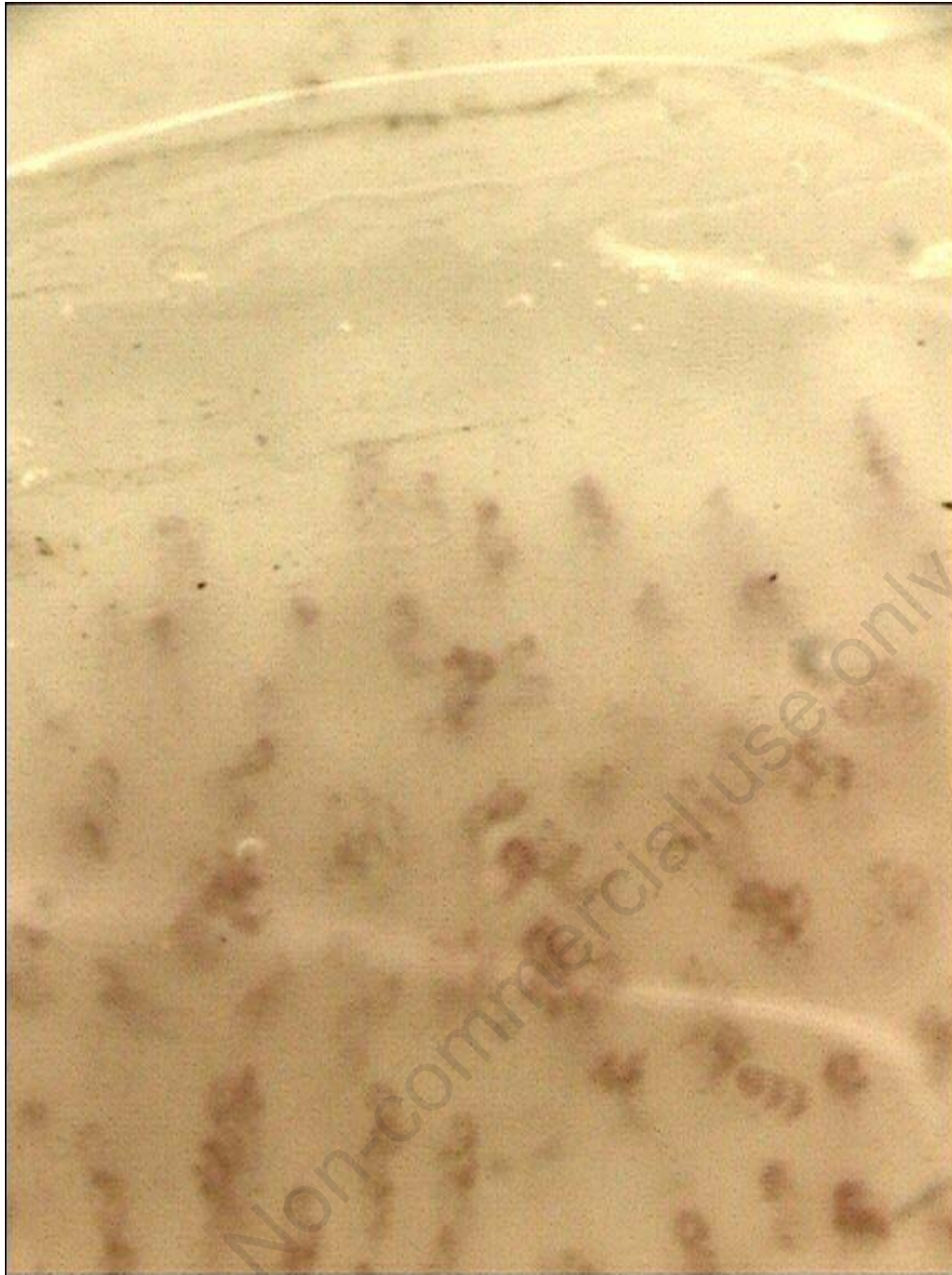

**Figure 2. Capillaroscopic pattern in Sjögren syndrome.**

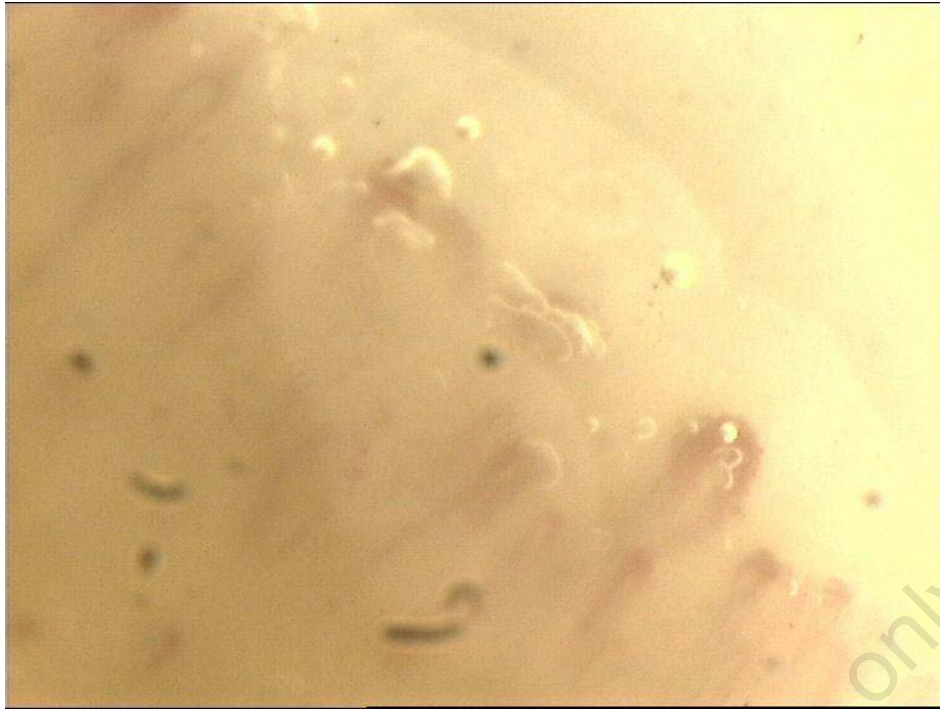


**Figure 3. Capillaroscopic pattern in rheumatoid arthritis.**

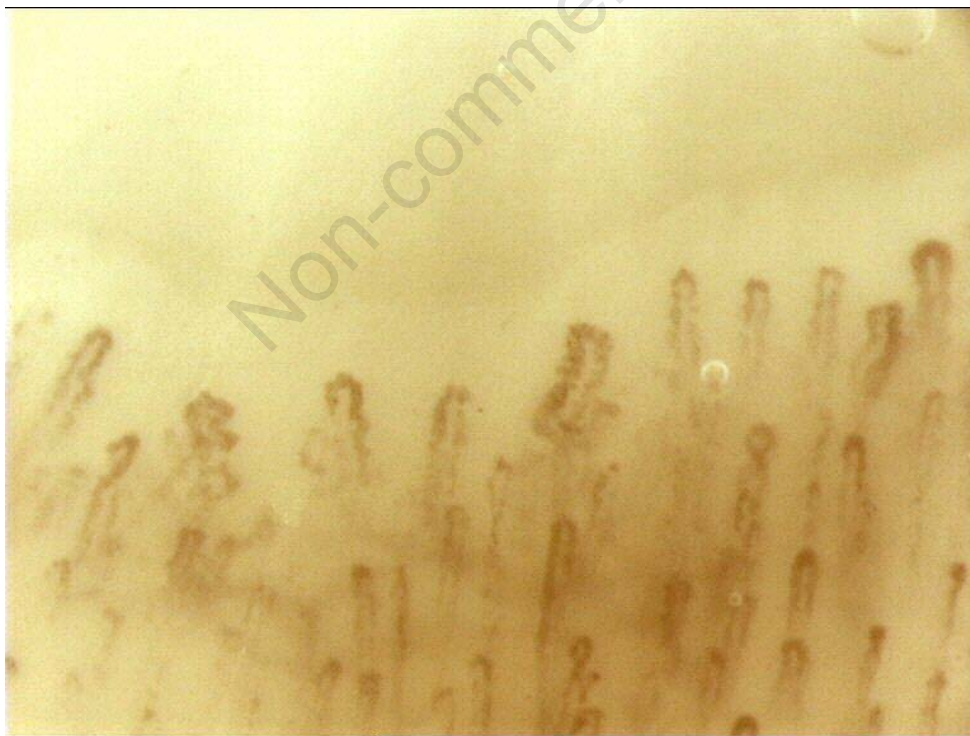Non-commercial use only



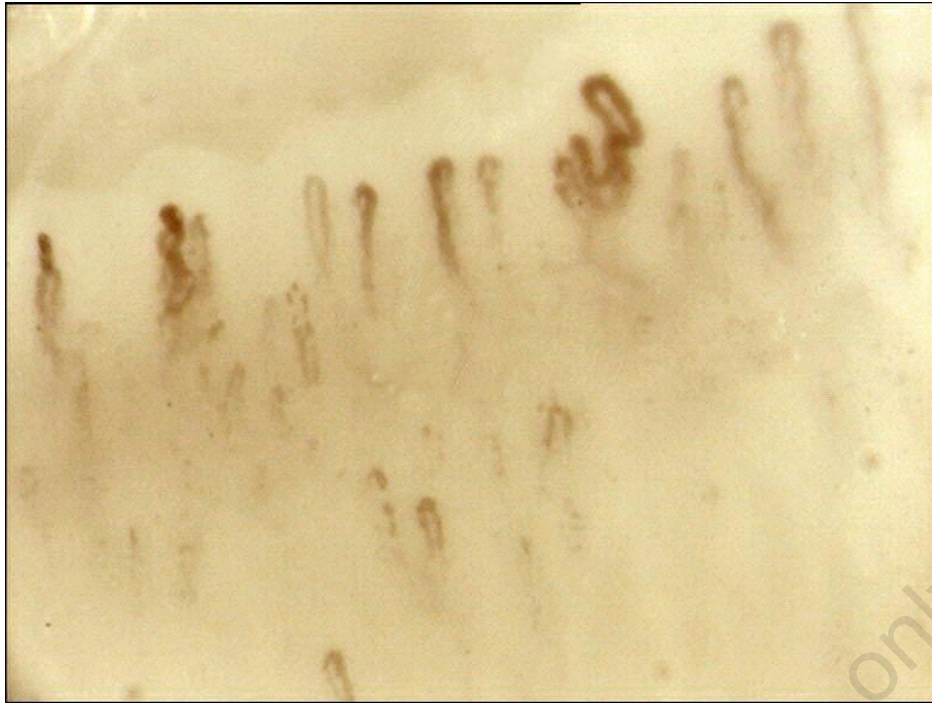**Figure 4. Capillaroscopic pattern in psoriatic arthritis.**



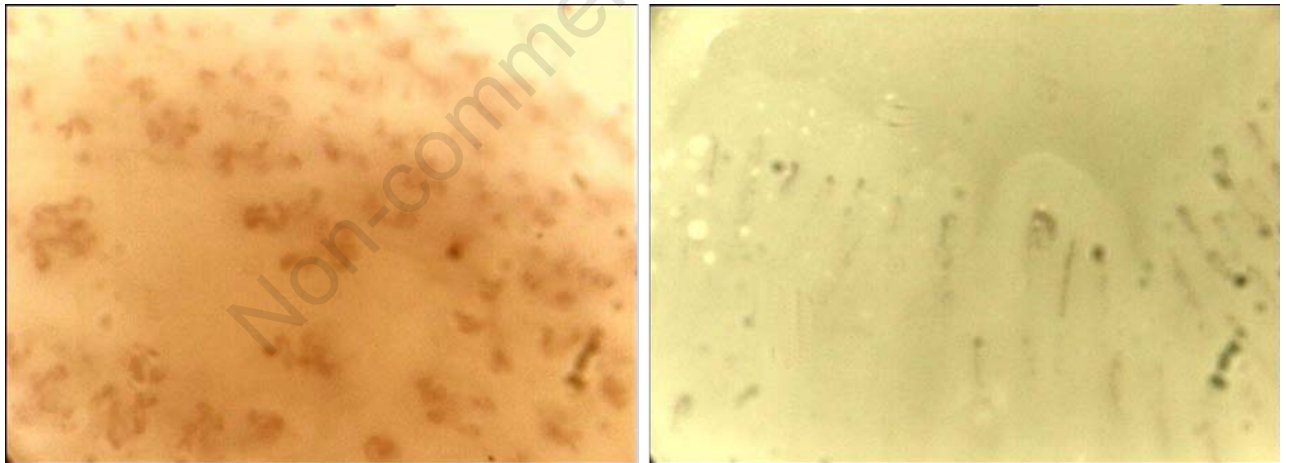
**Figure 5. Capillaroscopic pattern in primary biliary cirrhosis.**



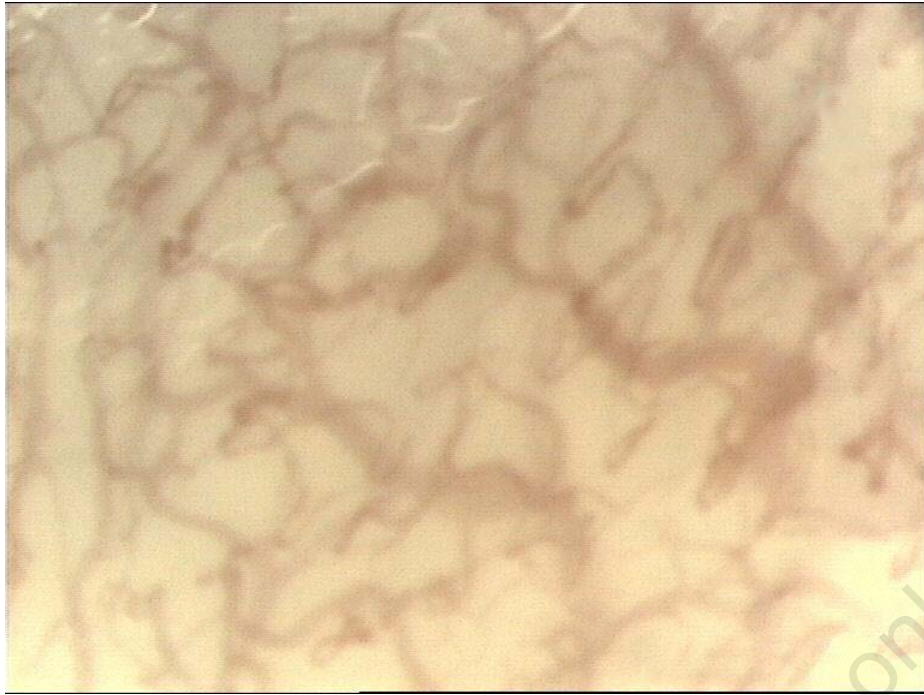
**Figure 6. Capillaroscopic aspect in mixed cryoglobulinemia.**



**Figure 7. Capillaroscopic aspect in diabetes.**



**Figure 8. Capillaroscopic aspect in peripheral artery disease hands and feet.**



**Figure 9. Oral capillaroscopy.**

Non-commercial use only