

When stenting in renal artery stenosis? Update on pathophysiology of ischemic nephropathy and management strategies

Alessandro Zuccalà, Renato Rapanà, Marcora Mandreoli

UOC Nefrologia e Dialisi, Ospedale S. Maria della Scaletta, AUSL Imola, Italy

ABSTRACT

In recent years, decisions taken on the optimal management of patients with renal artery stenosis have triggered off controversy and debate among clinicians dealing with renovascular disease. The main reason underlying this ongoing controversy may be the heterogeneity of the clinical entities that are normally associated with the umbrella definition of *renal artery stenosis*. Indeed a causal link between the stenosis and its clinical consequences (*i.e.* hypertension, renal failure) can often be demonstrated in some entities, such as fibromuscular dysplasia, truncal stenosis or arterial stenosis in the transplanted kidney, which can be defined as pure renal artery stenosis. On the contrary, the entity generally called ostial stenosis is a disease of the abdominal aorta where it encroaches the ostium of the renal artery at the end of a long process involving the entire vascular tree. Patients affected by ostial stenosis also suffer from generalized atherosclerosis, and kidney damage is often caused by the atherosclerotic environment with the stenosis acting as an innocent bystander. This may account for the low rate of renal function recovery in subjects with ostial stenosis. In our view, keeping the different entities separate along with a careful understanding of the mechanisms underpinning renal damage, particularly the intrarenal activation of the renin-angiotensin system which in turn induces renal inflammation and oxidative stress, may enable clinicians to make the right decisions in regard to revascularization.

Introduction

Over the last few decades, major advances in non-invasive vascular imaging have allowed an earlier detection of renovascular disease (RVD).¹ Atherosclerotic renal artery stenosis (ARAS) represents a common

manifestation of generalized atherosclerosis and is the predominant renal artery lesion in patients over 50 years of age and in patients with cardiovascular disease. It has been reported that the prevalence is about 7% in healthy elderly individual,² and 10-30% in patients with resistant hypertension,³ diabetes,^{4,5} coronary artery disease,⁶ peripheral artery disease,⁷ cerebrovascular disease⁸ and aortic aneurysm.⁹ The advent of interventional radiology and a growing familiarity with angioplasty and/or stenting techniques have recently prompted many cardiologists and interventional radiologists to opt for revascularization in all individuals with RVD. This approach has led to an increasing number of invasive treatments.¹⁰

However, there is no compelling clinical evidence supporting this approach, as the data from randomized controlled trials,¹¹⁻¹³ meta-analysis and systematic reviews¹⁴⁻¹⁶ does not enable clinicians to conclude that balloon angioplasty is superior to medical therapy in lowering blood pressure or in restoring renal function. Nevertheless, many clinicians are aware that some patients may benefit from revascularization, therefore the real challenge for them is to identify patients with renovascular disease who can potentially benefit from this procedure.

Since the decision as to the optimal management of patients with renal artery stenosis still triggers controversy and debate among cardiologist, internists and nephrologists, the aim of this review is to analyze the nature of the problems that make the management of patients with renal artery stenosis so controversial.

Correspondence: Alessandro Zuccalà, UOC Nefrologia e Dialisi, via Montericco 4, 40026 Imola, Italy.
Tel.: +39.0542.662543 - Fax: +39.0542.662544.
E-mail: alex4zuc@tiscali.it

Key words: renovascular disease, renal artery stenosis, ischemic nephropathy, percutaneous transluminal renal angioplasty, atherosclerotic renal disease.

Contributions: AZ, manuscript writing and reference search; RR, manuscript reviewing and reference search; MM, manuscript reviewing.

Conflict of interests: the authors declare no potential conflict of interests.

Received for publication: 18 June 2013.
Revision received: 19 September 2013.
Accepted for publication: 20 September 2013.

This work is licensed under a Creative Commons Attribution NonCommercial 3.0 License (CC BY-NC 3.0).

©Copyright A. Zuccalà et al., 2014
Licensee PAGEPress, Italy
Italian Journal of Medicine 2014; 8:148-157
doi:10.4081/ijm.2013.402

Role of age in the management of patients with renal artery stenosis

In 1962, Morris *et al.*¹⁷ reported a significant renal function recovery in some patients with azotemia caused by renal artery stenosis (RAS). Since then, other authors have reported clinical success in patients who had undergone surgery to salvage renal function.¹⁸⁻²⁰ Nevertheless the mean age of the patients treated in the 1960s and 1970s was drastically lower if compared to the current series. As reported by Tector and McKusick,²¹ the mean age of published series of patients submitted to renal revascularization over the last thirty years has risen by more than 15 years.

To further evaluate the role of age we have subdivided all the published series, according to the mean age of each series.²² We have correlated the percentage of favorable revascularization outcomes with the mean age of the respective groups and found an inverse correlation between the two parameters, *i.e.* the higher the mean age of the patients treated, the lower the percentage of renal function recovery. Furthermore, we identified an evident positive correlation between the mean age of the series and the rate of progression after revascularization (Figure 1).²³

Likewise a meta-regression analysis of 47 angioplasty studies has clearly shown an inverse relationship between the age of patients and the success in treating hypertension after revascularization.^{23,24}

Therefore this data corroborates the view that patient age should be carefully taken into account when selecting the therapeutic strategy.

Mismatch between Goldblatt experiment and clinical practice

The Goldblatt experiment²⁵ is a milestone in the conceptual approach to renovascular disease and is undoubtedly a powerful and innovative model that continues to influence the imagination of clinicians who deal with renal artery stenosis. Hence, when we think of renovascular disease, our view is still deeply shaped by Goldblatt's study. Yet it should be remembered that in Goldblatt's experiment renal artery clipping was performed in the context of a perfectly healthy vascular tree. A clinical situation that may mirror the Goldblatt's experiment is one in which the stenosis affects the renal artery in relatively young subjects whose vascular tree is not badly damaged. In clinical practice, this situation is frequently encountered in subjects suffering from fibromuscular dysplasia, non-ostial or truncal stenosis, and transplanted-kidney arterial stenosis. In recent years, the increasing prevalence of ostial lesions runs parallel with the increasing longevity of the population of the Western world. The declining mortality from

acute coronary disease allows for a gradual development of non-coronary atherosclerotic disease, which also affects the abdominal aorta and renal arteries.²⁶ Hence this kind of renal artery lesions is likely to occur at the end of a long-lasting atherosclerotic process that has already injured nearly all blood vessels of the body. In actual fact, ostial lesions are usually accompanied by a markedly diseased aorta, including the presence of an aortic aneurysm, and are associated with coronary artery disease, aorto-iliac and carotid atherosclerotic changes (Figure 2).²⁶

As a consequence, in these patients renal failure is hardly ever exclusively due to hypoperfusion caused by the narrowing of the renal artery, but rather to the atherosclerotic setting, *i.e.* a mixture of hypertensive damage, spontaneous cholesterol atheroembolism,^{27,28} intrarenal vascular disease, oxidative stress and systemic inflammation²⁹ (Figure 3).

In order to mimic the atherosclerotic milieu characteristic of patients with ostial stenosis, Chade *et al.*³⁰ superimposed cholesterol overfeeding to the classic clipping of renal artery in a group of pigs, and compared the kidney lesions of pigs with both high cholesterol and renal artery stenosis with those of pigs with pure renal artery stenosis.

The authors found that all types of kidney injuries (perivascular, tubulo-interstitial, and glomerular fibrosclerosis, kidney inflammation, tissue oxidative stress) were more severe in pigs treated by cholesterol overfeeding. Therefore this experiment stresses the importance of the atherosclerotic environment in inducing renal changes, besides renal artery stenosis. Moreover, additional experimental and clinical data³¹⁻³⁴ supports the hypothesis that there is no correlation between the patency of the lumen of renal arteries and the degree of renal failure in subjects with ARAS.

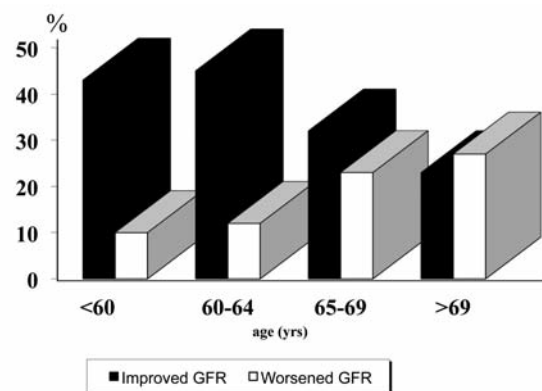


Figure 1. Percentage of subjects with improvement (black columns) or worsening (white columns) in glomerular filtration rate (GFR), after revascularization, according to the age range.

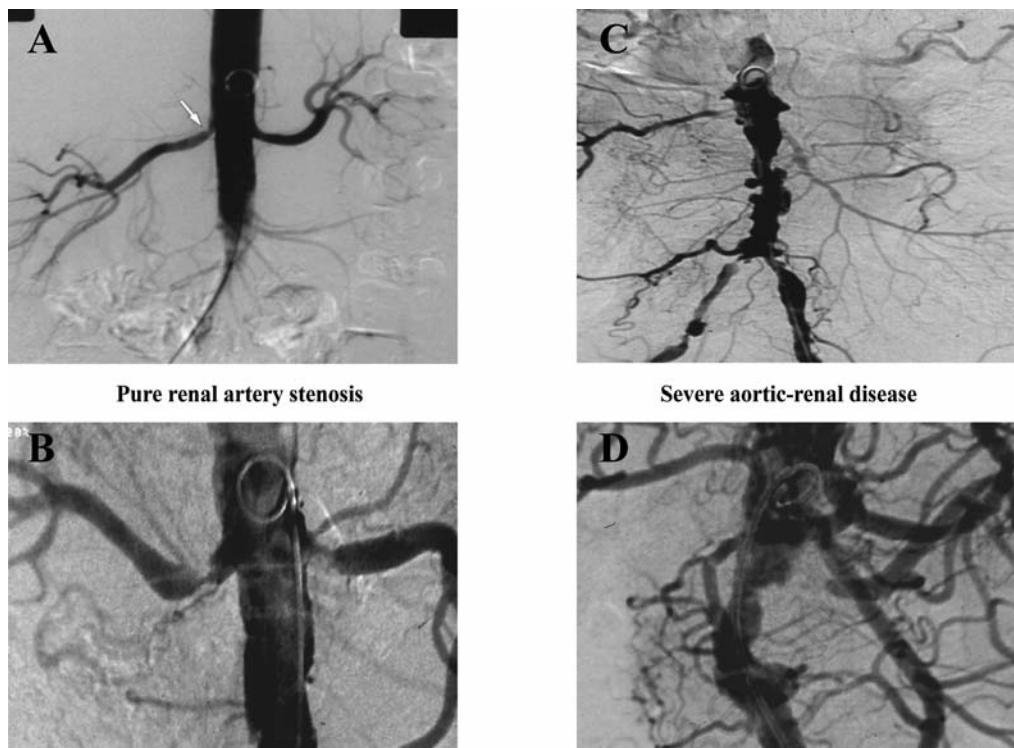


Figure 2. Examples of pure renal artery stenosis (A, B) and of aortic-renal vascular disease (or ostial stenosis) (C, D).

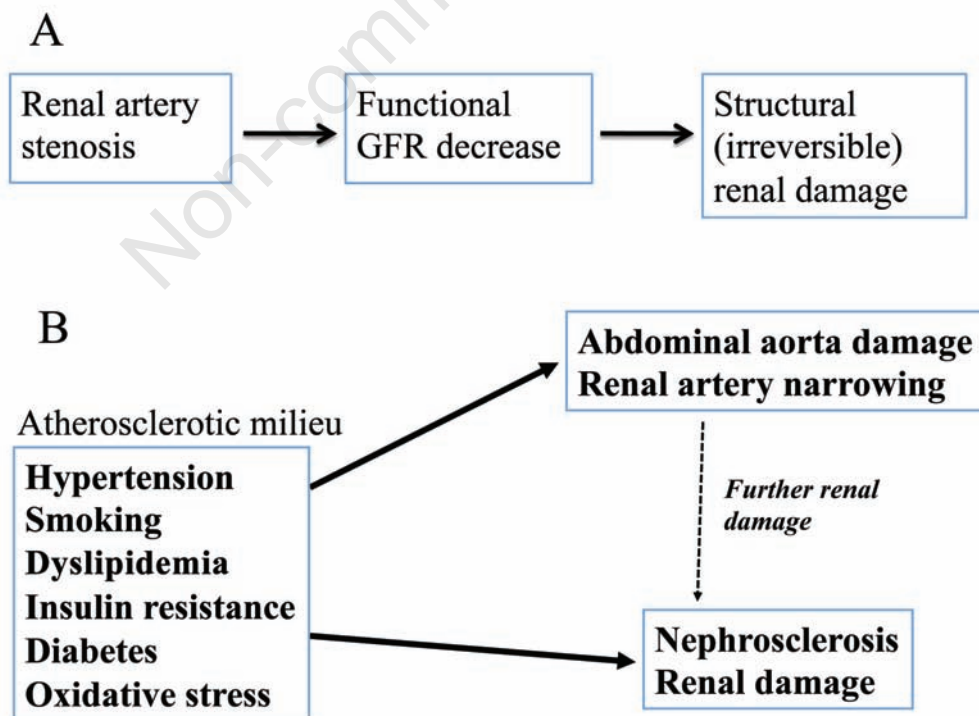


Figure 3. The mechanism of renal damage in patients with pure renal artery stenosis (A) and in patients with atherosclerotic aortic-renal disease (*i.e.* ostial stenosis) (B). GFR, glomerular filtration rate.

Also the percentage of patients with improved renal function after revascularization varies significantly when the patients with ostial stenosis are compared with the patients with pure renal stenosis. A few years ago we reviewed the literature in order to evaluate the outcome of revascularization in terms of renal function recovery according to the type of stenosis.²² We were able to identify the outcome of revascularization in 137 subjects with definite non-ostial or truncal stenosis, in 26 cases with well-documented renal failure caused by fibromuscular dysplasia (FD), and in 194 patients whose renal dysfunction was attributable to post-transplant renal artery stenosis (PTRAS). A significant improvement in renal function was reported in 44.5% of subjects with truncal stenosis, in 77% of cases with FD, and in 53% of patients with PTRAS submitted to revascularization. However, when we analyzed data concerning 419 subjects with well-documented ostial stenosis, we found an improvement in renal function only in 20% of patients.

In conclusion the aforementioned data suggests that in patients with pure RAS there is often a direct causal link between the stenosis and the functional decrease of glomerular filtration rate (GFR), whereas in most patients with ostial stenosis the renal damage is not linked to the renal artery narrowing.

Hence, clinicians are faced with a significant challenge: how to understand when renal artery stenosis is just an innocent bystander, and when it is instead the primary cause of kidney damage. To answer this question it may be useful to examine the mechanisms at the basis of the GFR decline, when renal artery stenosis is the real cause of renal damage.

Mechanisms of a functional, reversible decrease in glomerular filtration rate

The occurrence of renal artery stenosis gives rise to several compensatory mechanisms: an increased blood flow velocity at the site of stenosis; the activation of pressor mechanisms increasing systemic blood pressure in order to restore renal perfusion downstream to the stenosis; the vasodilation of preglomerular vessels to reduce intrarenal resistance to the blood flow, and lastly efferent arteriole constriction, through the activation of the intrarenal renin-angiotensin system (IRAS) to keep GFR normal in spite of the reduction in the glomerulus' hydraulic pressure. Only when the aforementioned compensatory mechanisms have been overcome, does the functional and reversible decline of GFR take place.³⁵

Hence by keeping in mind that activation of the IRAS is the last defense against the occurrence of the functional decline of GFR, it may be speculated that when the signs of IRAS activation are absent, a rapid

recovery of renal function after revascularization is unlikely. So, to return to clinical practice, it can be suggested that the search for signs of intrarenal activation on the renin-angiotensin system may be a useful tool to detect those patients in whom a recovery of renal function after revascularization is likely.³⁶

The structural, irreversible damage and the problem of the progression towards end-stage renal disease

Renal artery stenosis may also induce, in the long-term, irreversible renal damage by inducing renal interstitial fibrosis and glomerulosclerosis. On these grounds, by stressing the importance of preventing progressive renal damage some authors support revascularization in all patients with stenosis, because they consider renovascular disease always to be a progressive disease ending up in end-stage renal disease (ESRD).^{37,38}

There is no doubt that ARAS may be a progressive disorder. Indeed, stenosis sometimes progresses towards complete occlusion and, when the stenosis affects both kidneys or occurs in a solitary kidney, it may induce ESRD. However, the problem is this: how many stenoses will actually progress to occlusion? Also, if the process does not concern all the stenoses, how can we identify those at high risk of progression?

Early studies identified progression to renal occlusion in 14 to 50% of patients followed up for five years.^{39,40} In more recent series, an occlusion of the stenotic renal arteries was found in 3.1% of the subjects⁴¹ and a significant disease progression occurred in 11.1% of patients.⁴² It is important to consider that, in many series, patients were selected on the grounds of clinical signs such as resistant hypertension or unexplained renal failure. Therefore the conclusions should not be extrapolated/generalized to patients with a fortuitous diagnosis of RAS. Two series with a long-lasting follow up^{43,44} showed that when RAS was found as an incidental finding, for instance during angiography performed for peripheral artery disease, no patient reached end-stage renal failure, and serum creatinine levels remained stable throughout the follow-up.

The advocates of revascularization as a means of preventing end-stage renal disease underline that a growing number of subjects reaching ESRD have a diagnosis of ARAS.^{37,38} However, it should be considered that the coexistence of ARAS and ESRD does not prove a causal link between the two conditions.⁴⁵ Hence, to identify the patients in whom the revascularization may prevent the ESRD, it is important to understand the mechanisms at the root of progressive renal damage.

Mechanism of chronic structural damage

Through the activation of IRAS and the ensuing arteriole efferent constriction, stenosis may induce an increase in the filtration fraction and so the fractional sodium reabsorption increases in the affected kidney.⁴⁶ Since sodium reabsorption requires a large oxygen supply to the tubule - nearly 60% of the O₂ consumption occurs in the ascending loop of Henle - the mismatch between oxygen supply and oxygen requirement at the medulla level may be harmful. The activation of IRAS may also induce an oxidative stress since angiotensin II (AT2), acting on angiotensin II type 1 receptors (AT1R), induces an activation of superoxide production by the nicotinamide adenine dinucleotide phosphate oxidase, which is abundantly expressed in the kidney.⁴⁷ The superoxide production in turn, by inducing an inappropriate energy usage, due to the impairment of mitochondrial respiration, provokes a worsening of the imbalance between the oxygen supply and requirement.⁴⁸

Furthermore, it is recognized that AT2 is a potent activator of inflammation⁴⁹ because the AT1R activation of T cells is capable of activating chemokine pathways, leading to inflammation.^{50,51} Therefore, when the activation of IRAS takes place, it may trigger off

a cascade of events that end up in glomerular and tubulo-interstitial fibrosis and in micro-vessel loss which is no longer reversible (Figure 4).⁵²

The importance of the role of imbalance, at medullary level, between O₂ supply and tubular work, correlated with the IRAS activation, can explain an apparent paradox which at times occurs in clinical practice: a rapid decrease in GFR can play a protective role and can favor the functional recovery after the revascularization, as reported by Murray *et al.*,⁵³ who found that the faster the decline in GFR before revascularization, the better the renal function recovery after revascularization.

A second apparent paradox is that the occurrence of rapidly developing anuria can play a protective role, as demonstrated by some reports^{54,55} showing a total success rate in recovering renal function in anuric patients, even after several months of dialysis treatment.

The likely explanation for these somewhat puzzling events is that when a stenosis becomes severe in a short time, the glomerular filtration rate falls sharply, and in turn the overall sodium re-absorption and the consumption of oxygen rapidly decline.⁵² So perfusion pressures as low as 20 mmHg that provokes anuria can offer protection from parenchymal anoxic injury because the glomerular filtration rate and sodium deliv-

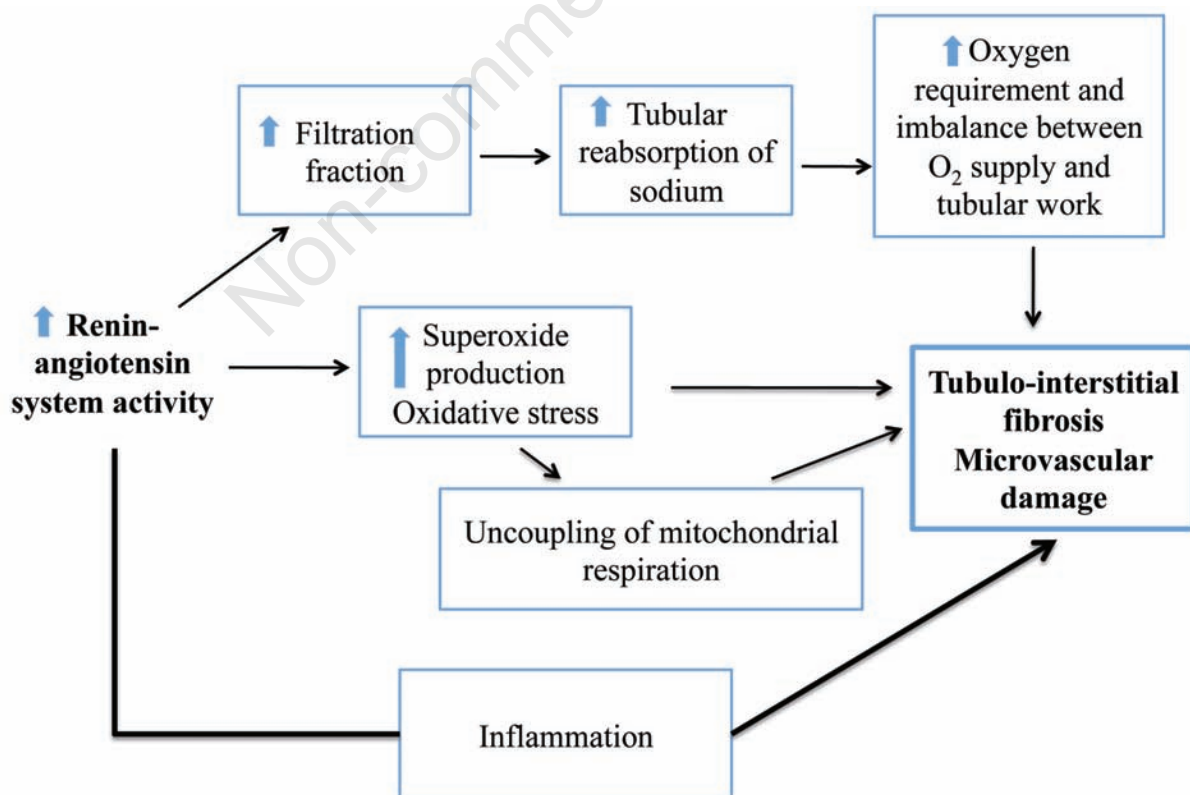


Figure 4. The chart shows the mechanisms that provoke structural, irreversible renal damage.

ery fall completely, and overall sodium re-absorption and oxygen consumption boil down to very little.

To sum up, there can be three scenarios in clinical practice: in the first one, the stenosis is not hemodynamically significant and then is the innocent bystander of the damage caused by the atherosclerotic environment; in the second, there is a *renal adaptation* to the stenosis⁵⁷ with simultaneous reductions in the blood flow and GFR and no activation of IRAS, no increase in the filtration fraction and the preservation of oxygenation, particularly at level of medullary region. For as long as this adaptation persists the kidney is protected from progressive structural damage. In third scenario, the stenosis induces the chronic activation of IRAS, which, in turn, triggers off inflammatory and oxidative pathways thereby inducing progressive renal damage that leads to ESRD. Once again, the signs of IRAS activation may be useful in order to detect patients at risk of progressive renal injury.

Prognostic criteria for treatment: computed tomography angiography, magnetic resonance angiography, Doppler, renography

Some diagnostic tools can be also used to predict the outcome of revascularization. Computed tomography angiography (CTA) and magnetic resonance angiography (MRA) are useful to identify whether high-grade stenosis is present, to determine whether lesions are bilateral, and are in a location suitable for endovascular or surgical repair. Furthermore, both CTA and MRA are useful to evaluate aortic wall damage and then the risk of athero-embolization during an endovascular maneuver.^{56,57}

Duplex Doppler ultrasonography can provide functional and structural assessment. Peak systolic velocity (PSV) measured by Doppler can be useful for evaluating the degree of luminal stenosis: previous studies have indicated that a 60% stenosis is associated with a PSV of 200 cm/s.⁵⁸ More recent studies have suggested that 60% stenoses are better detected with velocities >300 cm/s⁵⁹ and velocities >385 cm/s are commonly associated with renal hypoxia.⁶⁰ The resistive index (RI), measured at level of segmental arteries, can also be useful. RI is defined as height of PSV minus height of end-diastolic velocity divided by the PSV, and reflects the status of the flow characteristics in the renal microcirculation. An elevated RI reflects intrinsic parenchymal damage or small-vessel disease.⁵⁷ In some, but not in other⁶¹ studies, an RI>0.8 indicated no benefits after revascularization.

Taking into account the divergent data on RI, the approach in clinical practice might be the following: in the presence of a decrease in GFR, a normal RI (*i.e.*, <0.6) excludes structural kidney damage and indicates functional damage and therefore a likely recovery in renal

function after revascularization. However, an elevated RI (*i.e.*>0.8) does not always exclude an improvement in renal failure after revascularization, because a quota of functional, reversible decreases in GFR may sometimes be added on structural and irreversible lesions.

The use of captopril, radionuclide renography may act as prognostic index. The addition of captopril and the comparison with a baseline (non-captopril) renogram allow for the estimation of the functional role of angiotensin in maintaining glomerular filtration.⁶² Alternatively, the administration of an angiotensin converting enzyme (ACE) inhibitor or an angiotensin type 2 receptor (AT2R) blocker may be used as a prognostic tool: an acute elevation of serum creatinine (>30% above pre-treatment levels) after initiation of therapy detects the role of IRAS in preserving a normal GFR.³⁶ Studies in humans⁶³ have shown that the activation of IRAS does not occur until the pressure distal to the lesion falls at least by 10-20% below the pressure proximal to the lesion. This corresponds to translesional peak systolic gradients of 20-25 mmHg and degrees of luminal stenoses of 70-80%.⁶⁴

It should be noted that the diagnostic role of the renogram *i.e.* the search for the presence of a stenosis without considering its role in causing effect on renal circulation is not impressive, since renogram sensitivity ranges from 58 to 95% and its specificity ranges from 17 to 100%.⁶⁵

This wide range of sensibility and specificity is probably due to a bias of selection. Actually, an enrolment of subjects with a trivial stenosis (*i.e.* a narrowing of the lumen as 50% or less) can induce a reduction in the sensitivity of the renogram. On the other hand the enrolment of patients with some degree of volume depletion, which can activate the IRAS, can provoke a sharp decline of specificity.

However, the prognostic role of the renogram is conceptually very different from its diagnostic role. Just to provide an example: a negative renogram with a positive angiography is defined as a false negative if the renogram is used as a diagnostic tool. However, when it is used as a prognostic tool the right conclusion should be that the narrowing of renal artery (which is present) is not enough to activate the IRAS and therefore, as the activation of IRAS is the last step before the functional decrease of GFR, the absence of IRAS activation makes a recovery in GFR unlikely after revascularization.

The potential usefulness of a direct measurement of the pressure gradient has also been recognized for many years and the development of the miniaturized pressure sensor mounted near the tip of the angioplasty guidewire has made the measurement of pressure gradient more accurate.⁶⁶ However, direct measurement is by far more invasive than the evaluation of IRAS activation and should be used only in selected cases.

How to identify patients with atherosclerotic renal artery stenosis who will likely benefit from revascularization

At the end of this overview of the renal damage mechanisms, and waiting for the results of the ongoing trials,^{67,68} some conclusion can be drawn up that can help the clinician to make the right decision (Table 1).

First of all, we should always consider the clinical picture, particularly in patients with ostial stenosis. If acceptable blood pressure control can be achieved with an easily tolerated drug regimen and renal function remains stable, little is to be gained by undertaking hazardous and expensive vascular interventions.⁵⁷ Conversely, if successful blood pressure control remains hard to achieve, or additional conditions such as unexplained renal failure, a refractory congestive heart failure, or flash pulmonary edema⁶⁹ are present, both patients and physicians can better accept the risk of revascularization.

As regards the recovery of renal function in subjects with renal failure, the clinician should consider that:

- The older the patient to be treated is, the lower the likelihood of achieving renal function recovery.^{21,22}
- A badly damaged abdominal aorta is a drawback to revascularization. The clinician should evaluate the ratio between the severity of stenosis and the damage of aortic wall accurately: the best results will be obtained when stenosis is severe and the aorta wall is relatively well preserved (Figure 2B).²⁷
- The degree of stenosis must be proportionate to the severity of renal insufficiency. This means that only a severe bilateral stenosis or a severe stenosis in a solitary kidney (but not a unilateral stenosis) may be the cause of a significant decrease in GFR.³⁶
- The clinician should be reasonably certain that the stenosis is hemodynamically significant. The least invasive method is the evaluation of IRAS activation.^{56,57}

- The likelihood of a GFR recovery is inversely correlated to the presence of structural (irreversible) kidney tissue damage. The presence of an interstitial fibrosis or a nephroangiosclerosis can be evaluated by the measurement of RI by duplex ultrasonography.⁶¹

As regards the prevention of progressive renal damage and the prevention of ESRE, it should be borne in mind that:

- Progressive renal damage only involves a minority of the RAS subjects. Furthermore, in the case of the fortuitous detection of RAS, significant progression is rare.^{43,44}
- The progression of kidney disease is not always linked to the narrowing of RAS, as the atherosclerotic environment is important as well. Hence, it is likely that the improvement in medical therapy, due to the availability of more effective anti-cholesterol and anti-platelet drugs, may further slowdown the progression of renal damage.^{70,71} Furthermore, some innovative treatments, based on the infusion of vascular endothelial growth factor or mesenchymal cells have been successfully used in experimental settings.^{72,73}
- A treatment with ACE-inhibitors or AT2R-blockers should be set up in all patients with ARAS. This therapy could avoid chronic kidney damage related to IRAS activation,⁷⁴ and reduce mortality.⁷⁵ However, when the ACE-administration induces a significant decrease in GFR, revascularization should be taken into account.

Complications of renal artery stenting

The revascularization maneuver is not devoid of risks. In patients with ARAS, because of elastic recoil in ostial lesions, the restenosis incidence ranges be-

Table 1. Recommendations for the management of renovascular disease.

Factors in favor of a <i>wait and see</i> approach	Factors in favor of revascularization
Well-controlled blood pressure	Failure to achieve adequate blood pressure control with medical therapy
Stable renal function and stable renal artery stenosis on serial duplex ultrasound	Progressive decline in GFR notwithstanding good blood pressure control and a progressive narrowing of the stenosis
Advanced age and/or limited life expectancy	Rapid or recurrent decline in GFR during therapy with ACE-inhibitors or ARBs
Severe atherosclerotic damage of the abdominal aorta	Recurrent flash pulmonary edema
High risk or previous experience with atheroembolic disease	Bilateral stenosis or stenosis in the solitary kidney
Clinical or laboratory signs of other nephropathies (glomerulonephritis, diabetic nephropathy)	Activation of intrarenal renin-angiotensin system (radionuclide renogram)
High-resistive index (<i>i.e.</i> >0.8) with no sign of renin-angiotensin system activation	Renal insufficiency associated with low resistive index (<i>i.e.</i> <0.6)

GFR, glomerular filtration rate; ACE, angiotensin converting enzyme; ARBs, angiotensin II receptor blocker.

tween 20-47%. Introduction of stent has extended the efficacy of endovascular technique and the restenosis rate after stenting is about 20% at 1 year.

An attempt at revascularization may produce a systemic atheroembolic disease, at times with catastrophic results, particularly when severe aortic disease is present. Realistically, it may be envisaged that in at least 20% of these patients renal function will deteriorate after the revascularization procedures.^{28,76} As a preventive measure, embolic protection devices (EPD) have been applied in conjunction with renal artery stent placement. However the only prospective, randomized trial of embolic protection devices with renal stent placement demonstrated no difference between renal functional outcomes with or without the use of EPD.⁷⁷ Additional complications during renal artery stent placement include dissection and renal artery rupture. Iatrogenic renal artery perforation can occur from guidewire, angioplasty balloons, stents or even the guide catheter itself. Aortic dissections most likely occur as secondary to balloon-mediated intimal tears within the renal vasculature that eventually extend retrograde into the aorta. Intimal tears with contrast extravasation are the result of separation of the intima from the underlying media. Covered stents have been found to be effective in treating both coronary and iliac artery perforations. Extrapolation from these data has led to the use of covered stents for the treatment of renal artery dissections and perforations.⁷⁸

Another relatively frequent complication is contrast medium induced (CIN) nephropathy that occurs in about 5% of the maneuvers. N-acetyl cysteine, in a dose of 600 mg twice daily for 2 days, and/or sodium bicarbonate, have been advocated to lessening the risk of CIN. To prevent periprocedural thrombosis, patients commonly receive 325 mg of acetylsalicylic acid the day prior to the procedure. In patients with ARAS, clopidogrel 300 mg is often initiated the day before and 75 mg on the day of procedure. Patients who receive stents commonly are maintained on 325 mg acetylsalicylic acid for life and 75 mg clopidogrel for 1-3 months.

Conclusions

Stenosis of renal artery can lead to hypertension and to chronic renal failure, but the indications for revascularization are the subject of continuing debate. This is particularly true for ARAS which remains the most common condition and it is often incidentally detected. In patients with ARAS the challenge is to identify those patients who are likely to benefit from revascularization, avoiding useless and potentially dangerous maneuvers but also identifying the risk for ischemic irreversible injury at a time point when renal revascularization can still be of benefit to salvaging the kidney. A careful evaluation of clinical status, presence of as-

sociated aorto-iliac disease, entity of stenosis, presence of bilateral lesion, intrarenal activity of renin-angiotensin system, presence of an already irreversible renal damage is mandatory in order to enable clinicians to make the right decisions in regard to revascularization. A novel approach to avoid kidney tissue injury regardless of revascularization will be extremely useful.

References

1. Baumgartner I, Lerman LO. Renovascular hypertension: screening and modern management. *Eur Heart J* 2011; 32:1590-8.
2. Hansen KJ, Edwards MS, Craven TE, et al. Prevalence of renovascular disease in the elderly: a population-based study. *J Vasc Surg* 2002;36:443-51.
3. Van Jaarsveld BC, Krijnen P, Derkx FH, et al. Resistance to antihypertensive medication as predictor of renal artery stenosis: comparison of two drug regimens. *J Hum Hypertens* 2001;15:669-76.
4. Sawicki PT, Kaiser S, Heinemann L, et al. Prevalence of renal artery stenosis in diabetes mellitus - an autopsy study. *J Intern Med* 1991;229:489-92.
5. Zuccalà A, Losinno F, Zucchelli A, et al. Renovascular disease in diabetes mellitus: treatment by percutaneous transluminal renal angioplasty. *Nephrol Dial Transplant* 1998;13:26-9.
6. Rihal CS, Textor SC, Breen JF, et al. Incidental renal artery stenosis among a prospective cohort of hypertensive patients undergoing coronary angiography. *Mayo Clin Proc* 2002;77:309-16.
7. Missouri CG, Buckenham T, Cappuccio FP, et al. Renal artery stenosis: a common and important problem in patients with peripheral vascular disease. *Am J Med* 1994; 96:10-4.
8. Kuroda S, Nishida N, Uzu T, et al. Prevalence of renal artery stenosis in autopsy patients with stroke. *Stroke* 2000;31:61-5.
9. Olin JW, Melia M, Young JR, et al. Prevalence of atherosclerotic renal artery stenosis in patients with atherosclerosis elsewhere. *Am J Med* 1990;88:46N-51N.
10. Dworkin LD. Controversial treatment of atherosclerotic renal vascular disease. The cardiovascular outcomes in renal atherosclerotic lesions trial. *Hypertension* 2006; 48:350-6
11. van Jaarsveld BC, Krijnen P, Pieterman H, et al. The effect of balloon angioplasty on hypertension in atherosclerotic renal-artery stenosis. *N Engl J Med* 2000;342: 1007-14.
12. Webster J, Marshall F, Abdalla M, et al. Randomised comparison of percutaneous angioplasty vs continued medical therapy for hypertensive patients with atheromatous renal artery stenosis. *J Hum Hypertens* 1998; 12:329-35.
13. Plouin PF, Chatellier G, Darne B, Raynaud A. Blood pressure outcome of angioplasty in atherosclerotic renal artery stenosis: a randomized trial. *Hypertension* 1998; 31:823-9.
14. Isles CG, Robertson S, Hill D. Management of renovascular disease: a review of renal artery stenting in ten studies. *Q J Med* 1999;92:159-67.

15. Balk E, Raman G, Cheung M, et al. Systematic review: comparative effectiveness of management strategies for renal artery stenosis. *Ann Intern Med* 2006;145:901-12.
16. ASTRAL Investigators, Wheatley K, Ives N, et al. Revascularization versus medical therapy for renal artery stenosis. *N Engl J Med* 2009;361:1953-62.
17. Morris GC, DeBakey ME, Cooley DA. Surgical treatment of renal failure of renovascular origin. *JAMA* 1962;182:609-12.
18. Novick A, Pohl M, Schreiber M, et al. Revascularization for the preservation of renal function in patients with atherosclerotic renovascular disease. *J Urol* 1983;129:907-12.
19. Kaylor WM, Novick AC, Ziegelbaum M, Vidt DG. Reversal of end-stage renal failure with surgical revascularization in patients with atherosclerotic renal artery occlusion. *J Urol* 1989;141:486-8.
20. Ascer E, Gennaro M, Rogers D. Unilateral renal artery revascularization can salvage renal function and terminate dialysis in selected patients with uremia. *J Vasc Surg* 1993;18:1012-8.
21. Textor SC, McKusick M. Renovascular hypertension and ischemic nephropathy: angioplasty and stenting. In: Brady HR, Wilcox CS, eds. *Therapy in nephrology and hypertension*. London: WB Saunders; 2003. pp 599-609.
22. Zuccalà A, Losinno F, Lifrieri F, Di Nicolò P. Renal artery stenosis: a unique disease or a broad spectrum of different diseases? *Curr Hypertens Rev* 2007;3:270-6.
23. Morganti A, Lonati C. Renal angioplasty for treatment of hypertensive patients with fibromuscular dysplasia. No country for old men. *J Hypertens* 2013;31:1091-93.
24. Trinquart L, Mounier-Vehier C, Sapoval M, et al. Efficacy of revascularization for renal artery stenosis caused by fibromuscular dysplasia: a systematic and meta-analysis. *Hypertension* 2010;56:525-32.
25. Goldblatt H, Lynch J, Hanzal RF, et al. Studies on experimental hypertension: production of persistent elevation of systolic blood pressure by mean of renal ischemia. *J Exp Med* 1934;59:347-79.
26. Metcalfe W, Reid A, Geddes CC. Prevalence of angiographic atherosclerotic renal artery disease and its relationship to the anatomical extent of peripheral vascular atherosclerosis. *Nephrol Dial Transplant* 1999;14:105-8.
27. Zuccala A, Zucchelli P. A renal disease frequently found at postmortem, but rarely diagnosed in vivo. *Nephrol Dial Transplant* 1997;12:1762-7.
28. Scolari F, Tardanico R, Zani R, et al. Cholesterol crystal embolism: a recognizable cause of renal disease. *Am J Kidney Dis* 2000;36:1089-109.
29. Mimuz P, Patrignani P, Gaino S, et al. Increased oxidative stress and platelet activation in patients with hypertension and renovascular disease. *Circulation* 2002;106:2800-5.
30. Chade AR, Rodriguez-Porcel M, Grande JP, et al. Mechanisms of renal structural alterations in combined hypercholesterolemia and renal artery stenosis. *Arterioscler Thromb Vasc Biol* 2003;23:1295-301.
31. Urbietta-Caceres VH, Lavi R, Zhu XY, et al. Early atherosclerosis aggravates the effect of renal artery stenosis on the swine kidney. *Am J Physiol Renal Physiol* 2010;299:F135-40.
32. Lerman LO, Taler SJ, Textor SC, et al. Computed tomography-derived intrarenal blood flow in renovascular and essential hypertension. *Kidney Int* 1996;49:846-54.
33. Suresh M, Laboi P, Mamtora H, Kalra PA. Relationship of renal dysfunction to proximal arterial disease severity in atherosclerotic renovascular disease. *Nephrol Dial Transplant* 2000;15:631-6.
34. Farmer CK, Cook GJ, Blake GM, et al. Individual kidney function in atherosclerotic nephropathy is not related to the presence of renal artery stenosis. *Nephrol Dial Transplant* 1999;14:2880-4.
35. Zucchelli P, Zuccalà A. Ischaemic nephropathy. In: Davison AM, Cameron JS, Grunfeld JP, Kerr DNS, Ritz E, Vinerals CG, eds. *Oxford textbook of clinical nephrology*. 2nd ed. Oxford: Oxford University Press; 1998. pp 1445-1456.
36. Zuccala A, Zucchelli P. Atherosclerotic renal artery stenosis - when is intervention by PTA or surgery justified? *Nephrol Dial Transplant* 1995;10:585-7.
37. Morganti A. Angioplasty of the renal artery: antihypertensive and renal effects. *J Nephrol* 2000;13:S28-33.
38. van Ampting JM, Penne EL, Beek FJ, et al. Prevalence of atherosclerotic renal artery stenosis in patients starting dialysis. *Nephrol Dial Transplant* 2003;18:1147-51.
39. Tollefson DFJ. Natural history of atherosclerotic renal artery disease associated with aortic disease. *J Vasc Surg* 1991;14:327-31.
40. Rimmer JM, Gennari FJ. Atherosclerotic renovascular disease and progressive renal failure. *Ann Intern Med* 1993;118:712-9.
41. Caps MT, Zierler RE, Polissar NL, et al. Risk of atrophy in kidneys with atherosclerotic renal artery stenosis. *Kidney Int* 1998;53:735-42.
42. Crowley JJ, Santos RM, Peter RH, et al. Progression of renal artery stenosis in patients undergoing cardiac catheterisation. *Am Heart J* 1998;136:913-8.
43. Leertouwer TC, Pattinama PMT, van den Berg-Huisman A. Incidental renal artery stenosis in peripheral vascular disease. A case for treatment? *Kidney Int* 2001;39:1480-3.
44. Iglesias JJ, Hamburger RJ, Feldman L, Kaufman JS. The natural history of incidental renal artery stenosis in patients with aortoiliac vascular disease. *Am J Med* 2000;109:642-7.
45. Main J. How important is atheromatous renal artery stenosis as a cause of end stage renal disease? *Semin Dialysis* 2001;14:143-6.
46. Gomez SL, Warner L, Haas JA, et al. Increased hypoxia and reduced renal tubular response to furosemide detected by BOLD magnetic resonance imaging in swine renovascular hypertension. *Am J Physiol Renal Physiol* 2009;297:F981-6.
47. Welch WJ, Blau J, Xie H, et al. Angiotensin-induced defects in renal oxygenation: role of oxidative stress. *Am J Physiol Heart Circ Physiol* 2005;288:H22-8.
48. Evans RG, Gardiner BS, Smith DW, O'Connor PM. Intrarenal oxygenation: unique challenges and the biophysical basis of homeostasis. *Am J Physiol Renal Physiol* 2008;295:F1259-70.
49. Hirono Y, Yoshimoto T, Suzuki N, et al. Angiotensin II receptor type-1-mediated vascular oxidative stress and proinflammatory gene expression in aldosterone induced hypertension. The possible role of local renin-angiotensin system. *Endocrinology* 2007;148:1688-96.
50. Lerman LO, Textor SC, Grande JP. Mechanisms of tis-

- sue injury in renal artery stenosis ischemia and beyond. *Prog Cardiovasc Dis* 2009;52:196-203.
51. Textor SC, Lerman LO. Inflammatory cell markers as indicators of atherosclerotic renovascular disease. *Clin J Am Soc Nephrol* 2012;7:193-95.
 52. Eirin A, Gloviczki ML, Tang H, et al. Inflammatory and injury signals released from the post-stenotic human kidney. *Eur Heart J* . 2013;34:540-8.
 53. Murray S, Martin M, Amoedo ML, et al. Rapid decline in renal function reflects reversibility and predicts the outcome after angioplasty in renal artery stenosis. *Am J Kidney Dis* 2002;39:60-6.
 54. Dean RH, Tribble RW, Hansen KJ, et al. Evolution of renal insufficiency in ischemic nephropathy. *Ann Surg* 1991;213:446-55.
 55. van Damme H, Rorive G, Limet R. Reversal of acute renal failure by kidney revascularisation. *Eur J Vasc Endovasc Surg* 1996;11:134-9.
 56. Zuccalà A. L'imaging dell'ipertensione renovascolare. *G Ital Nefrol* 2005;22:226-34.
 57. Herrmann SM, Textor SC. Diagnostic criteria for renovascular disease: where are we now? *Nephrol Dial Transplant* 2012;27:2657-63.
 58. Zeller T, Bonvini RF, Sixt S. Color-coded duplex ultrasound for diagnosis of renal artery stenosis and as follow-up examination after revascularization. *Catheter Cardiovasc Interv* 2008;71:995-9.
 59. Chi YW, White CJ, Thornton S, Milani RV. Ultrasound velocity criteria for renal in-stent restenosis. *J Vasc Surg* 2009;50:119-23.
 60. Gloviczki ML, Lerman LO, Textor SC. Blood oxygen level-dependent (BOLD) MRI in renovascular hypertension. *Curr Hypertens Rep* 2011;13:370-7.
 61. Zeller T, Müller C, Frank U, et al. Stent angioplasty of severe atherosclerotic ostial renal artery stenosis in patients with diabetes mellitus and nephrosclerosis. *Catheter Cardiovasc Interv* 2003;58:510-5.
 62. Derckx FH, Schalekamp MA. Renal artery stenosis and hypertension. *Lancet* 1994;344:237-9.
 63. De Bruyne B, Manoharan G, Pijls NH, et al. Assessment of renal artery stenosis severity by pressure gradient measurements. *J Am Coll Cardiol* 2006;48:1851-5.
 64. Drieghe B, Madaric J, Sarno G, et al. Assessment of renal artery stenosis: side-by-side comparison of angiography and duplex ultrasound with pressure gradient measurements. *Eur Heart J* 2008;29:517-24.
 65. Vasbinder GB, Nelemans PJ, Kessels AG, et al. Renal artery stenosis: optimizing diagnosis and treatment. *Ann Intern Med* 2001;135:401-11.
 66. Mangiacapra F, Trana C, Sarno G, et al. Translesional pressure gradients to predict blood pressure response after renal artery stenting in patients with renovascular hypertension. *Circ Cardiovasc Interv* 2010;3:537-42.
 67. Cooper CJ, Murphy TP, Matsumoto A, et al. Stent revascularization for the prevention of cardiovascular and renal events among patients with renal artery stenosis and systolic hypertension: rationale and design of the CORAL trial. *Am Heart J* 2006;152:59-66.
 68. Rossi GP, Seccia TM, Miotto D, et al. The Medical and Endovascular Treatment of Atherosclerotic Renal Artery Stenosis (METRAS) study. Rationale and study design. *J Hum Hypertens* 2012;26:507-16.
 69. Messerli FH, Bangalore S, Makani H, et al. Flash pulmonary oedema and bilateral renal artery stenosis: the Pickering syndrome. *Eur Heart J* 2011;32:2231-5.
 70. Meier P. Statin therapy in ARAS: beyond cholesterol lowering. *Am J Hypertens* 2008;21:1075.
 71. Silva VS, Martin JC, Franco RJS, et al. Pleiotropic effect of statins may improve outcomes in atherosclerotic renovascular disease. *Am J Hypertens* 2008;21:1163-8.
 72. Chade AR, Zhu X, Lavi R et al. Endothelial progenitor cells restore renal function in chronic experimental renovascular disease. *Circulation* 2009;119:547-57.
 73. Eirin A, Zhu XY, Krier JD, et al. Adipose tissue-derived mesenchymal stem cells improve revascularization outcomes to restore renal function in swine atherosclerotic renal artery stenosis. *Stem Cells* 2012;30:1030-41.
 74. Zhang X, Eirin A, Li ZL, et al. Angiotensin receptor blockade has protective effects on the poststenotic porcine kidney. *Kidney Int* 2013;84:767-75.
 75. Losito A, Errico R, Santirosi P, et al. Long-term follow-up of atherosclerotic renovascular disease. Beneficial effect of ACE inhibition. *Nephrol Dial Transplant* 2005; 20:1604-9.
 76. Hiramoto J, Hansen KJ, Pan XM, et al. Atheroemboli during renal artery angioplasty: an ex-vivo study. *J Vasc Surg* 2005;41:1026-30.
 77. Cooper CJ, Haller St, Clyer W, et al. Embolic protection and platelet inhibition during renal artery stenting. *Circulation* 2008;117:2752-60.
 78. Friedel JM, Khalil R, Lasorda D. Treatment of iatrogenic renal artery perforation with a covered stent and subsequent rheolytic thrombectomy. *J Invasive Cardiol* 2005;17:374-5.