



CASO CLINICO

# Eosinophilic gastroenteritis: a case report and review of the literature

*Gastroenterite eosinofila: a proposito di un caso clinico e revisione della letteratura*

Paolo Biagi<sup>a</sup>, Luigi Abate<sup>b,\*</sup>, Carmine Mellone<sup>c</sup>, Stefania Salvadori<sup>b</sup>,  
Andrea Peccetti<sup>c</sup>, Alessandro Ginori<sup>d</sup>

<sup>a</sup> UOC Medicina Interna USL-7 (Dir. Dott. Paolo Biagi), Montepulciano (SI)

<sup>b</sup> UOC Medicina Interna USL-7 (Dir. Inc. f.f. Dott. Luigi Abate), Montepulciano (SI)

<sup>c</sup> Servizio di Endoscopia Digestiva (Responsabile Dott. Carmine Mellone), Montepulciano (SI)

<sup>d</sup> Dipartimento Patologia Umana ed Oncologia, Sezione Anatomia Patologica, Università di Siena

Received 29 January 2012; accepted 28 May 2012

Available online 11 July 2012

## KEY WORDS

Eosinophilic gastrointestinal diseases;  
Eosinophilic gastroenteritis;  
Eosinophilia.

## Summary

**Background:** Eosinophilic gastroenteritis (EoG) is a rare disease of unknown etiology characterized by patchy or diffuse eosinophilic infiltration of the gastrointestinal tract wall. As clinical presentation and endoscopic/ radiological findings are nonspecific, diagnosis may only be ascertained by histologic findings.

**Clinical case:** This article presents a case of EoG with associated colonic involvement but without peripheral eosinophilia. Although no allergy could be demonstrated, the clinical symptoms and histologic pattern of diffuse eosinophilic mucosal infiltration disappeared after steroid therapy, as discovered by a careful endoscopic follow-up.

**Discussion:** Current concepts of this complex disorder and a review of the literature are presented.

© 2012 Elsevier Srl. All rights reserved.

## Introduction

Eosinophilic gastrointestinal diseases (EGIDs) are a heterogeneous group of diseases (eosinophilic esophagitis [EoE],

eosinophilic gastroenteritis [EoG], eosinophilic ileocolitis [EoIC] and eosinophilic colitis [EoC]) characterized by gastrointestinal symptoms and increased eosinophils in the intestinal parietal wall [1].

\* Corresponding author: Via Cocconi 3 – Acquaviva di Montepulciano (Siena).  
E-mail: [villabercio@tiscali.it](mailto:villabercio@tiscali.it) (L. Abate).

Initial descriptions of EGIDs schematically divided patients into subtypes with respect to the anatomical location, i.e., mucosal (with the ensuing symptoms of diarrhea and bleeding), muscular (obstruction), and serosal (ascites) disease. Recent descriptions characterize the mucosal forms in more detail [2,3].

Eosinophilic gastroenteritis, an idiopathic inflammation of the alimentary canal, is characterized by infiltration of the intestinal wall by eosinophils, massive submucosal edema, and peripheral eosinophilia; it is generally confined to the gastric antrum and proximal small intestine [4]. Eosinophilic ileocolitis is extremely rare [5–7], and the colon is rarely cited as a unique site for the condition [8,9].

The diagnosis for EGIDs is established after ruling out other causes of an eosinophilic disease, particularly atopy, parasitic infestations, vasculitis, and hypereosinophilic syndrome (HES).

We report a typical case of widespread EoG with associated involvement of colonic mucosa in which symptoms dramatically responded to a course of steroids, as discovered by careful follow up.

## Case report

A 64-year-old man was admitted to the Internal Medicine Department complaining of watery diarrhea (approximately 20 stool passages/d) and weight loss but not abdominal pain nor vomiting. He had no history of abdominal surgery or any other allergic disease. He denied taking any medication or herbal medicines.

A physical examination of the abdomen was negative.

Initial laboratory investigations showed a normal white blood cell count with an absolute eosinophil count of 76/mm<sup>3</sup>, low albumin (3 g/dL), low IgG (497 mg/dL) and increased IgE (282 U/ml). Tests for antinuclear factor, rheumatoid factor, and antineutrophilic cytoplasmic autoantibody were all negative.

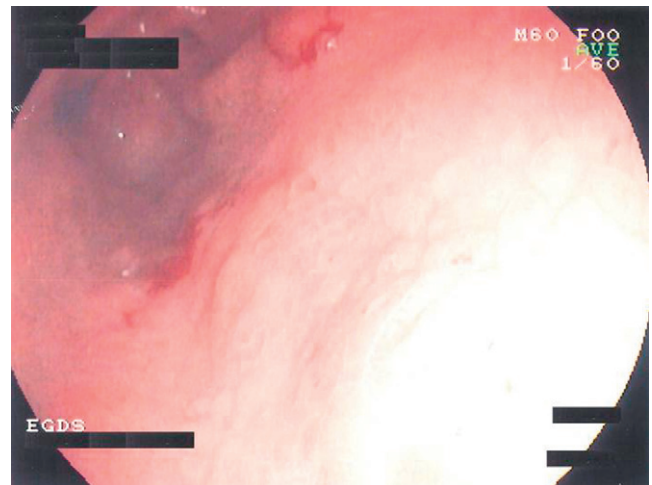
Celiac disease and thyroid in vitro function tests as well as hepatitis A, B and C markers were negative. Carcinoembryonic Antigen (CEA) was 23 ng/ml (NV < 5 ng/ml); Ca 19-9, Ca 125, Ca 15-3 and AFP were within normal range.

Stool examination for ova and parasites were negative as well as RAST testing for a battery of allergens, including common foods. The abdomen CT scan was normal with the exception of minimal widening of the ascending colonic wall.

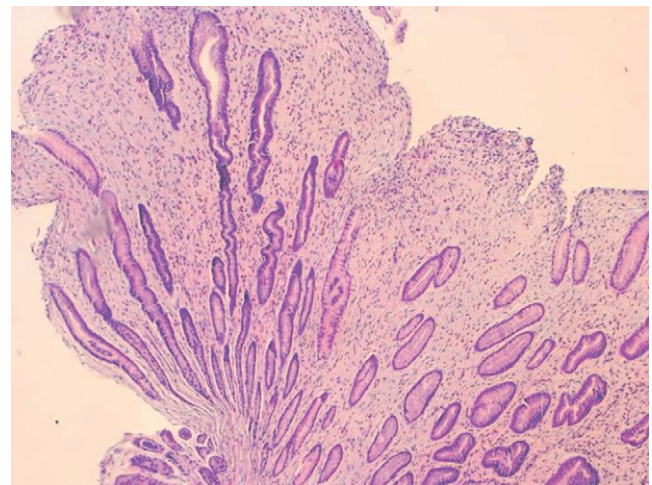
A gastroscopy showed marked edema of the gastric antrum, narrowing of the pyloric ring and edema of the duodenal mucosa with erythema (Fig. 1). Biopsies of the gastric antrum and proximal and distal duodenum revealed flattening of microvilli and inflammation with eosinophilic infiltration (Fig. 2). A colonoscopy showed marked patches of erythema, mucosal edema and some small sigmoid diverticula (Fig. 3). Biopsies of the rectum, sigmoid and ascending colon revealed architectural distortion and dilatation of cryptae, microabscesses and eosinophilic infiltration of the colonic mucosa (Fig. 4).

Prednisolone at 50 mg/d was prescribed. Complete remission of the diarrhea occurred in approximately one week, and the patient was discharged for follow-up.

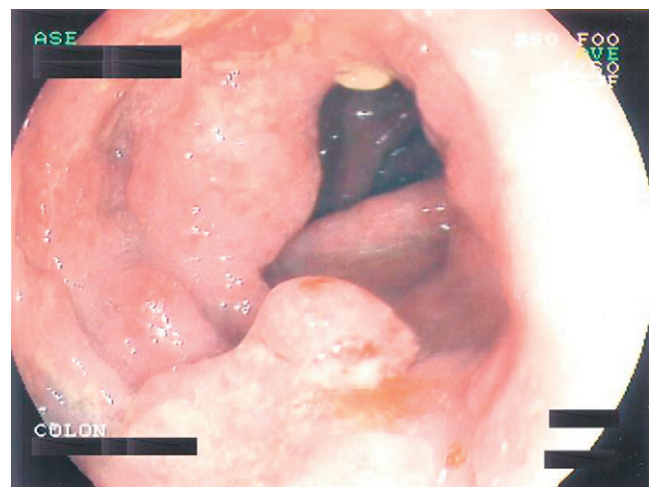
Approximately one month later, the patient's bowel habits were normal, and he had gained 2 kg. A new gastroscopy was



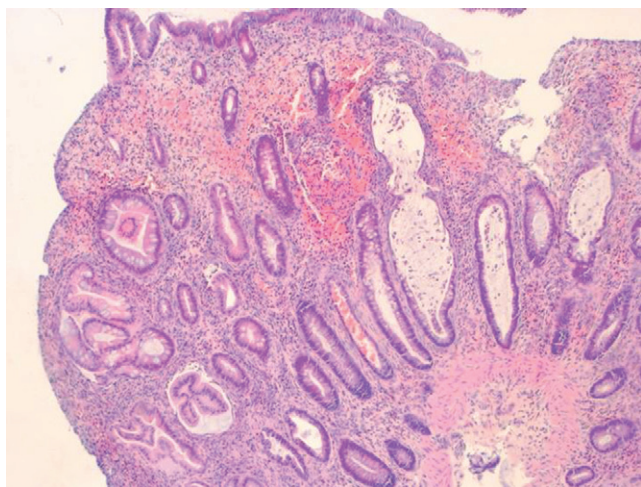
**Figure 1** EGDS. marked edema of the gastric antrum, some erosions and narrowing of the pyloric ring.



**Figure 2** Antral gastric mucosa showing huge edema of the lamina propria and numerous eosinophil infiltrates (E.E. x 50).



**Figure 3** Colon: patched marked erythema, minimal erosions, mucosal edema, and some small sigmoid diverticula.



**Figure 4** Colonic mucosa with mild architectural distortion, erosions and crypts dilatation with eosinophilic microabscesses. (E.E. x 50).

near normal with a histologic pattern of minimal fibrosis of the lamina propria without eosinophils, while the endoscopic pattern of the colonic mucosa still showed cryptae with eosinophil microabscesses and eosinophil infiltration of the tunica propria.

Prednisone was continued at the same dosage.

After two months, the patient was still asymptomatic. Further endoscopic investigation revealed normal gastric and duodenal endoscopic patterns and histologic findings, while a colonoscopy showed only mild erythema at the sigmoid mucosa but no edema. Biopsies in both the upper GI tract and colon showed a minimal or near normal presence of eosinophils in the middle layers of the mucosa. Prednisone was tapered and discontinued over a one-month time period; no recurrence was observed. After six months the patient was well and denied further endoscopic evaluation.

## Discussion

Eosinophilic gastroenteritis can involve any part of gastrointestinal tract from the esophagus down to the rectum. The stomach and duodenum are the most common sites of involvement [10–13].

Four criteria are required for the diagnosis of EoG: the presence of gastrointestinal symptoms, eosinophilic infiltration of the gastrointestinal tract, exclusion of parasitic disease or other identifiable cause of eosinophilia and the absence of other systemic involvement [1, 14, 15].

Eosinophils are normal constituents of the mucosa of the gastrointestinal tract; however, the number of eosinophils that can be defined as normal in a biopsy specimen has not been clearly defined [16].

Peripheral eosinophilia is not necessary to make a diagnosis, but it is present in approximately two-thirds of patients and is more prevalent in the serosal than in the mucosal and muscular disease forms [15–17].

The epidemiology of other EGIDs is unknown; approximately 300 cases have been reported in the medical literature since the initial description of this disease by Kaiser [17].

The data are limited to case reports and small series, but it is reasonable to hypothesize that it may be more frequent. Approximately 50% of patients with EoG have a history of allergies (e.g., asthma, rhinitis, drug/food allergy and eczema) [8, 9, 18, 19] and as a result, food allergens and cytokines have been proposed to play a role in an immune-mediated mechanism of eosinophilic inflammation. It is well known that eosinophils can mediate proinflammatory effects by releasing Th2-cytokines (IL-3, IL-5 and IL-13), transforming growth factor (TGF- $\alpha/\beta$ ), chemokines, platelet activating factor (PAF) and leukotriene C4 and can induce tissue damage by eosinophilic cation protein (ECP), peroxidase, major basic protein (MBP) and lipid mediators [2]. The presence of peripheral eosinophilia, abundant eosinophils in the gastrointestinal tract, T cell proliferation in the lamina propria, secretion of IL-13 in response to milk protein [11, 20] and finally the dramatic response to steroids support the hypothesis that EGID may be an IgE mediated disease.

In our case of EGID, apart from the esophagus, all intestinal anatomical locations (stomach, duodenum, colon) were involved. There was no history of allergy. There was no correlation between the diffuse eosinophilic mucosal infiltration of the whole intestine and the clinical symptoms. The localization to the colonic mucosa could help to explain the watery diarrhea and mild malabsorption syndrome (moderate weight loss and borderline hypoalbuminemia, hypocholesterolemia, hypotriglyceridemia, hypocalcemia) observed in this patient.

After steroid therapy was started at doses near those used in inflammatory bowel disease (1–2 mg/kg/d), the patient's diarrhea stopped in a few days. Endoscopic follow-up showed a sharp gastric and duodenal histological improvement, but eosinophilic infiltration of the entire colon was still evident in biopsy specimens at two months.

Eosinophils in the intestinal mucosa may be seen in various diseases (see Tab. 1).

**Table 1** Classification and differential diagnosis of eosinophilic gastroenteritis.

### Primary eosinophilic gastroenteritis

- Mucosal
- Muscular
- Serosal

### Secondary eosinophilic gastroenteritis and/or differential diagnosis

- Infections and parasitic infestations
- Hypereosinophilia syndrome
- Inflammatory bowel disease
- Celiac disease
- Autoimmune disease, vasculitis
- Connective tissue disease
- Medications
- Transplantation
- Inflammatory fibroid polyps

Modified from Khan S. Eosinophilic gastroenteritis Best Practice & Research Clinical Gastroenterology 2005; Vol. 19, No. 2, pp. 177–198.

In our case, the patient was not taking any medication, and there was no exposure to toxic substances.

Hypereosinophilic syndrome (HES) may be associated with gastroenteritis but was ruled out because it is an idiopathic condition characterized by marked peripheral eosinophilia exceeding 1500 cells/ $\mu$ l for six consecutive months and its major targets are the heart, lung, brain and kidneys, with >55% of patients presenting with a complication in  $\geq$ 1 of these sites [21].

Celiac disease was excluded on the basis of the biopsy specimen of duodenal mucosa obtained at follow-up and the negative serological antibodies pattern. On the basis of clinical and laboratory findings, systemic vasculitis [22], autoimmune diseases, scleroderma and polymyositis [23] could be reasonably ruled out as well. Bacterial infections (*Helicobacter pylori*, etc.) and parasitic infestations (*Ascariidosis*, *Anisakiasis*, *Enterobiasis*, *Anchylostomiasis*, *Trichina*, *Teniasis*, etc.) are a well-known cause of EoG [24–27], but in our patient neither bacteria in gastric biopsies or stool culture nor ova and parasites were found in the stools.

Eosinophils may also be present in Inflammatory Bowel Disease [28] and Crohn's disease [29,30]; eosinophilic colitis (EoC) and Crohn's disease may be present in the same subject [31].

Most commonly, EoG may be the consequence of food allergy; a positive IgE RAST test or prick test makes it possible to remove the putative food allergen. Non-IgE-mediated allergies, implicated in the pathogenesis of EoG, pose more difficulty [2]; the diagnosis relies on the results of elimination diets, selected oral food challenges, and biopsies.

In our case, no positive food allergen could be demonstrated and the colonic involvement makes it similar to the pure form of EoC, in which a positive IgE RAST test is rarely found [20].

Otherwise, we observed a six-fold increase in total IgE in this patient and although we neither have supportive tests for food-induced allergy nor did attempt elimination diets, the very good clinical response to steroids supports the hypothesis of an IgE-mediated phenomenon [32–34].

The conclusions from this case may be summarized in the following remarks:

1. the widespread involvement of the intestinal mucosa with involvement of the entire colon,
2. symptoms characterized only by watery diarrhea associated with a minimal malabsorption syndrome,
3. the absence of a well-defined substance which may have triggered an IgE phenomenon, suggesting steroids as the first choice for treatment,
4. a good clinical response with no recurrence, and rapid improvement of the endoscopic and histologic gastric patterns with a less rapid improvement of histologic findings in the colon.

This clinical case was carried out in accordance with the ethical standards established in the Declaration of Helsinki. The patient gave informed consent to treatment and to the publication of the results.

## Conflict of interest

The authors have no conflicts of interests to disclose.

## References

- [1] Furuta GT, Forbes D, Boey C, Dupont C, Putnam P, Roy SK, et al., EGDs Working Group. Eosinophilic Gastrointestinal Diseases (EGIDs). *Journal of Pediatric Gastroenterology and Nutrition* 2008;47:234–8.
- [2] Rothenberg ME. Eosinophilic gastrointestinal disorders (EGID). *J Allergy Clin Immunol* 2004;113:11–28.
- [3] Chang JY, Choung RS, Lee RM, Locke GR, Schleck CD, Zinsmeister AR, et al. A shift in the clinical spectrum of eosinophilic gastroenteritis toward the mucosal disease type. *Clin Gastroenterol Hepatol* 2010;8:669–772.
- [4] Kerr PJ. Eosinophilic gastroenteritis: clinical experience with 15 patients. *World J Gastroenterol* 2004;10:2923–6.
- [5] Verger P, Blais J, Hamon JF, Senghor C, Haffaf Y. Eosinophilic ileocolitis: two case reports. *Rev Méd Interne* 1998;19:841–2.
- [6] Tedesco FJ, Huckaby CB, Hamby-Allen M, Ewing GC. Eosinophilic ileocolitis: expanding spectrum of eosinophilic gastroenteritis. *Dig Dis Sci* 1981;26:943–8.
- [7] Haberkern CM, Christie DL, Haas JE. Eosinophilic gastroenteritis presenting as ileocolitis. *Gastroenterology* 1978;74:896–9.
- [8] Naylor AR, Pollet JE. Eosinophilic colitis. *Dis Colon Rectum* 1985;28:615–8.
- [9] Velchuru VR, Khan AB, Hellquist HB, Studley JG. Eosinophilic Colitis. *J Gastrointest Surg* 2007;11:1373–5.
- [10] Daneshjoo RJ, Talley N. Eosinophilic gastroenteritis. *Curr Gastroenterol Rep* 2002;4:366–72.
- [11] Khan S, Orenstein SR. Eosinophilic gastroenteritis. *Gastroenterol Clin North Am* 2008;37:333–48.
- [12] Chen MJ, Chu CH, Lin SC, Shih SC, Wang TE. Eosinophilic gastroenteritis: clinical experience with 15 patients. *World J Gastroenterol* 2003;9:2813–6.
- [13] Khan S. Eosinophilic gastroenteritis. *Best Pract Res Clin Gastroenterol* 2005;19:177–98.
- [14] Baig MA, Qadi A, Rasheed JA. Review of Eosinophilic Gastroenteritis. *J National Medical Association* 2006;98:1616–9.
- [15] Straumann A. Idiopathic eosinophilic gastrointestinal diseases in adults. *Best Practice & Research Clinical Gastroenterology* 2008;22(3):481–96.
- [16] Okpara N, Aswad B, Baffy G. Eosinophilic colitis. *World J Gastroenterol* 2009;15:2975–9.
- [17] Talley NJ, Shorter RG, Phillips SF, Zinsmeister AR. Eosinophilic gastroenteritis: a clinicopathological study of patients with disease of the mucosa, muscle layer and subserosal tissues. *Gut* 1990;31:54–8.
- [18] Straumann A, Simon HU. The physiological and pathophysiological roles of eosinophils in the gastrointestinal tract. *Allergy* 2004;59:15–25.
- [19] Kaijser R. Zur Kenntnis der allergischen Affektionen des Verdauungskanals vom Standpunkt des Chirurgen aus. *Arch. Klin Chir* 1937;188:36–64.
- [20] Klein NC, Hargrove RL, Sleisenger MH, Jeffries GH. Eosinophilic gastroenteritis. *Medicine (Baltimore)* 1970;49(4):299–319.
- [21] Scudamore HH, Phillips SF, Swedlund HA, Gleich GJ. Food allergy manifested by eosinophilia, elevated immunoglobulin E level, and protein-losing enteropathy: the syndrome of allergic gastroenteropathy. *J Allergy Clin Immunol* 1982;70:129–38.
- [22] Conus S, Simon H. General laboratory diagnostics of eosinophilic GI diseases. *Best Practice & Research Clinical Gastroenterology* 2008;22(3):441–53.
- [23] Roufosse F, Cogan E, Goldman M. Recent advances in pathogenesis and management hypereosinophilic syndromes. *Allergy* 2004;59:673–89.
- [24] Solans R, Bosch JA, Perez-Bocanegra C, Selva A, Huguet P, Alijotas J, et al. Churg-Strauss syndrome: outcome and long-term follow up of 32 patients. *Rheumatology (Oxford)* 2001;40:763–71.

- [25] DeSchryver-Kecskemeti K, Clouse RE. A previously unrecognized subgroup of 'eosinophilic gastroenteritis'. Association with connective tissue diseases. *Am J Surg Pathol* 1984;8: 171–80.
- [26] Muller MJ, Sewell GS. Coexistence of eosinophilic gastroenteritis and *Helicobacter pylori* gastritis: causality versus coincidence. *Dig Dis Sci* 2001;46:1784–6.
- [27] Macedo T, MacCarty RL. Eosinophilic ileocolitis secondary to *Enterobius vermicularis*: case report. *Abdom Imaging* 2000;25: 530–2.
- [28] Esteve C, Resano A, Diaz-Tejeiro P, Fernandez-Benitez M. Eosinophilic gastritis due to *Anisakis*: a case report. *Allergol Immunopathol* 2000;28:21–3.
- [29] Takeyama Y, Kamimura S. Eosinophilic colitis with high antibodytiter against *Ascaris Suum*. *J Gastroenterol Hepatol* 2003;26: 341–6.
- [30] Choy MY, Walker-Smith JA, Williams CB, MacDonald TT. Activated eosinophils in chronic inflammatory bowel disease. *Lancet* 1990;14(336):126–7.
- [31] Jeziorska M, Haboudi N, Schofield P, Wolley DE. Distribution and activation of eosinophils in inflammatory bowel disease using an improved immunohistological technique. *J Pathol* 2001;194: 484–92.
- [32] Wedemeyer J, Vosskuhl K. Role of gastrointestinal eosinophils in inflammatory bowel disease and intestinal tumours. *Best Pract Res Clin Gastroenterol* 2008;22:537–49.
- [33] Katsanos KH, Zinovieva E, Lambri E, Tsianos EV. Eosinophilic-Crohn overlap colitis and review of the literature. *J Crohn's and Colitis* 2011;5:256–61.
- [34] Ingle SB, Patle YG, Murdeshwar HG, Pujari GP. A case of early eosinophilic gastroenteritis with dramatic response to steroids (letter to editor). *Journal of Crohn's and Colitis* 2011;5:71–2.