

Obesity: a potential cause of varicocele leading to male infertility

Zain ul Hasan,¹ Syed Amir Gilani,² Asif Hanif,³ Raham Bacha,¹ Zareen Fatima¹

¹University Institute of Radiological Sciences and Medical Imaging Technology (UIRSMIT), The University of Lahore, Pakistan; ²Department of Medicine and Allied Health Sciences, Green International University, Lahore, Pakistan; ³Department of Biostatistics, Faculty of Medicine, Sakarya University, Sakarya, Turkey

ABSTRACT

Male infertility is the root cause of social, psychological, economic, and medical problems. Obesity, culminating in varicocele, is one of the leading causes of male infertility. Veins of the lower abdomen are compressed by excessive subcutaneous fat, and the return of blood from the scrotum is compromised. This increases the intratesticular temperature, which decreases sperm quality. The objective of this study was to determine the influence of obesity on male infertility, particularly varicocele development. This cross-sectional study was conducted for 18 months with 172 men. The participants were categorized into obese and nonobese groups. Color Doppler ultrasound was performed to detect varicocele and related conditions. A chi-square test was applied to determine the associations between obesity and infertility with respect to varicocele. A significant association of varicocele with obesity was noted ($p < 0.05$). The odds of the development of varicocele in obese individuals was 2.4 and the relative risk was 2.12 compared to nonobese individuals. In the nonobese group, 22 (25.5%) and 41 (47.67%) patients in the obese group were infertile. Compared with 25.5% of nonobese and infertile subjects, 47.6% of obese and infertile subjects concluded that a greater percentage of obese and infertile subjects were diagnosed with varicocele than nonobese and infertile subjects.

Correspondence: Zain ul Hasan, University Institute of Radiological Sciences and Medical Imaging Technology (UIRSMIT), The University of Lahore, Pakistan.
E-mail: gilani_zain@yahoo.com

Key words: male infertility, varicocele, obesity, scrotum, testes.

Contributions: ZH, writing- original draft, data curation, resources, validation; SAG, supervision, writing – review and editing, project administration, data curation; AH, software; RB, methodology, conceptualization, writing of the original draft, writing– review and editing; ZF, writing- review and editing, formal analysis, data curation.

Conflict of interest: the authors declare that the research was conducted in the absence of any commercial or financial relationships that could be construed as potential conflicts of interest.

Ethical approval and consent to participate: the study was approved by Research Ethical Committee Faculty of Allied Health Sciences, The University of Lahore (No:REC-UOL-/235/03/21).

Informed consent: written informed consent was obtained from all the participants

Funding: none.

Availability of data and materials: the data are available upon request due to privacy/ethical restrictions.

Received: 10 October 2024.
Accepted: 20 November 2024.

Publisher's note: all claims expressed in this article are solely those of the authors and do not necessarily represent those of their affiliated organizations, or those of the publisher, the editors and the reviewers. Any product that may be evaluated in this article or claim that may be made by its manufacturer is not guaranteed or endorsed by the publisher.

©Copyright: the Author(s), 2024
Licensee PAGEPress, Italy
Italian Journal of Medicine 2024; 18:1827
doi:10.4081/ijm.2024.1827

This work is licensed under a Creative Commons Attribution NonCommercial 4.0 License (CC BY-NC 4.0).

to determine the associations between obesity and infertility with respect to varicocele. A significant association of varicocele with obesity was noted ($p < 0.05$). The odds of the development of varicocele in obese individuals was 2.4 and the relative risk was 2.12 compared to nonobese individuals. In the nonobese group, 22 (25.5%) and 41 (47.67%) patients in the obese group were infertile. Compared with 25.5% of nonobese and infertile subjects, 47.6% of obese and infertile subjects concluded that a greater percentage of obese and infertile subjects were diagnosed with varicocele than nonobese and infertile subjects.

Introduction

Male infertility is a major social, economic, and medical problem affecting a large proportion of the human population.¹ In the developing world, only females are considered the cause of infertility and are treated.² Amongst the various causes of male infertility, varicocele is one of the most important causes of male infertility, although it is either not considered a cause of infertility or not diagnosed properly. This is either due to some socioeconomic issues or the shyness of the patients to share their problem with colleagues, elders, or doctors.³ A myriad of clinical conditions give rise to male infertility, ranging from simple infection to testicular cancer, azoospermia, and even the absence of testes. Scrotal pathologies are among the major causes of infertility. In most health delivery systems, only semen analysis relies upon male infertility, but this analysis can reveal only the health and count of sperm, not the cause. With the use of ultrasound, the cause of male infertility can be determined. Early diagnosis and timely treatment can help reduce the number of infertility cases.⁴

Common tests of male reproductive function include the measurement of serum testosterone levels. The normal range of testosterone that circulates freely in plasma is 50 to 210 pg/mL.⁵ The total testosterone concentration ranges from 300 to 1000 ng/mL in normal fertile individuals.⁶ Other tests include semen analysis, which establishes the fertility status and function of the seminiferous tubules, epididymis, and accessory sex glands.⁷ A sperm sample is collected and examined microscopically for count, motil-

ity, and shape. It can be useful in diagnosing cases of infertility. Normal sperm counts are typically greater than 15 million/mL and motility is greater than 40%.^{8,9}

Varicocele is considered the most common cause of male infertility. Its frequency in infertile couples is approximately 49.4%. Ovulation disorders are considered the most common cause in females, and their prevalence is 57.5%.¹⁰ The causes of infertility are highly complex. In recent years, many couples have delayed starting a family to focus on their careers. As a consequence of advanced maternal and paternal age, couples face difficulty conceiving and are undergoing infertility investigations.¹¹ Even though physically fit, the couple might experience some social and psychological stress that impedes the process of conception.¹²

Ultrasonography is commonly utilized in the evaluation and diagnosis of male factor infertility and functions as an adjunctive method for use with assisted reproductive techniques.¹³ In addition to the ability to visualize anatomic detail in real-time, enhancements of Doppler, power Doppler, and duplex Doppler provide information on underlying physiologic and pathologic processes.¹⁴ Varicocele is one of the most important causes of male infertility.¹⁵ Ultrasonography provides significant information for both the initial evaluation and diagnosis of male factor infertility and may be used concomitantly at the time of surgery for the management of select obstructive etiologies. As ultrasound technology continues to improve, it may play an increasingly central role in the management of infertile males.¹⁶

Materials and Methods

Selection and description of the participants

This cross-sectional analytical study was conducted for 18 months after the approval of the Institutional Research Ethical Committee. The calculated sample size was 172, in which systematic random sampling was considered. Written informed consent was obtained from all the participants. Those with clinical evidence of infertility or with a previous history of testicular trauma or surgery were excluded from the study. The included subjects were divided into two groups on the basis of their body mass index (BMI): obese (BMI>25) and nonobese (BMI<25). There were 86 participants in each of the two groups.

Data collection and measurement

The sample was calculated *via* the statistical sample size power formula. A Toshiba Xario instrument equipped with a linear transducer with a frequency range of 7-14 Hz

was used. Grayscale, color, power, and pulsed Doppler were used for the scanning of patients. The American Institute of Ultrasound in Medicine guidelines for the scrotal ultrasound were used.¹⁷ Patients were positioned supine, and the scrotum was supported and distended by having the patient gently pull the penis upward. A water-based gel followed by a transducer was moved gently over the scrotal area, and the vein diameter was measured on a grayscale on both sides by making color Doppler ultrasound assessments.¹⁷ Color Doppler settings optimized for low flow detection included a velocity scale of approximately 3 cm/s, a minimal wall filter, and maximum gain without artifacts. Blood flow direction was observed during Valsalva and normal respiration to detect reflux. Vein diameter >2.5mm and blood flow reflux indicated varicocele.¹⁸

Statistics

The chi-square test was applied *via* the Statistical Package for Social Sciences (SPSS) version 27 to determine the associations of obesity with varicocele and infertility. The odds ratio (OR) and relative risk (RR) were also calculated. A p-value less than 0.05 was considered significant.

Results

Among the 172 subjects, 25 were diagnosed with varicocele, of whom 17 patients were obese, and 8 were nonobese (Table 1). These proportions indicate that varicocele development occurred in 68% of the obese patients compared with 32% of the nonobese patients. A significant association of varicocele with obesity was observed ($p<0.05$). OR of varicocele formation in obese patients was 2.4, and the RR was 2.12. Figures 1 and 2 show the ultrasound images of subjects diagnosed with varicocele.

In the nonobese group, 64 (74.5%) and 22 (25.5%) patients were fertile and infertile, respectively, whereas in the obese group, 45 (52.33%) and 41 (47.67%) patients were fertile and infertile, respectively. Since the majority of the varicocele-positive subjects were obese (17) and infertile (23), it can be inferred that a larger percentage of obese and infertile subjects were diagnosed with varicocele than nonobese and infertile subjects were.

Table 2 shows that varicocele was also significantly associated with infertility ($p<0.0001$). However, oligospermia was detected in 22 (95.7%) of the 23 infertile patients with varicocele and 21 (52.5%) of the 40 infertile patients without varicocele (Table 3). Both tables indicate that varicocele development alone is not responsible for infertility but is caused by many other factors, with obesity being one such factor, as indicated by our findings.

Table 1. Association between obesity and varicocele.

	Varicocele		Total
	No	Yes	
Obese	69	17	86 (50%)
Non-Obese	78	8	86 (50%)
	147 (85.5%)	25 (14.5%)	

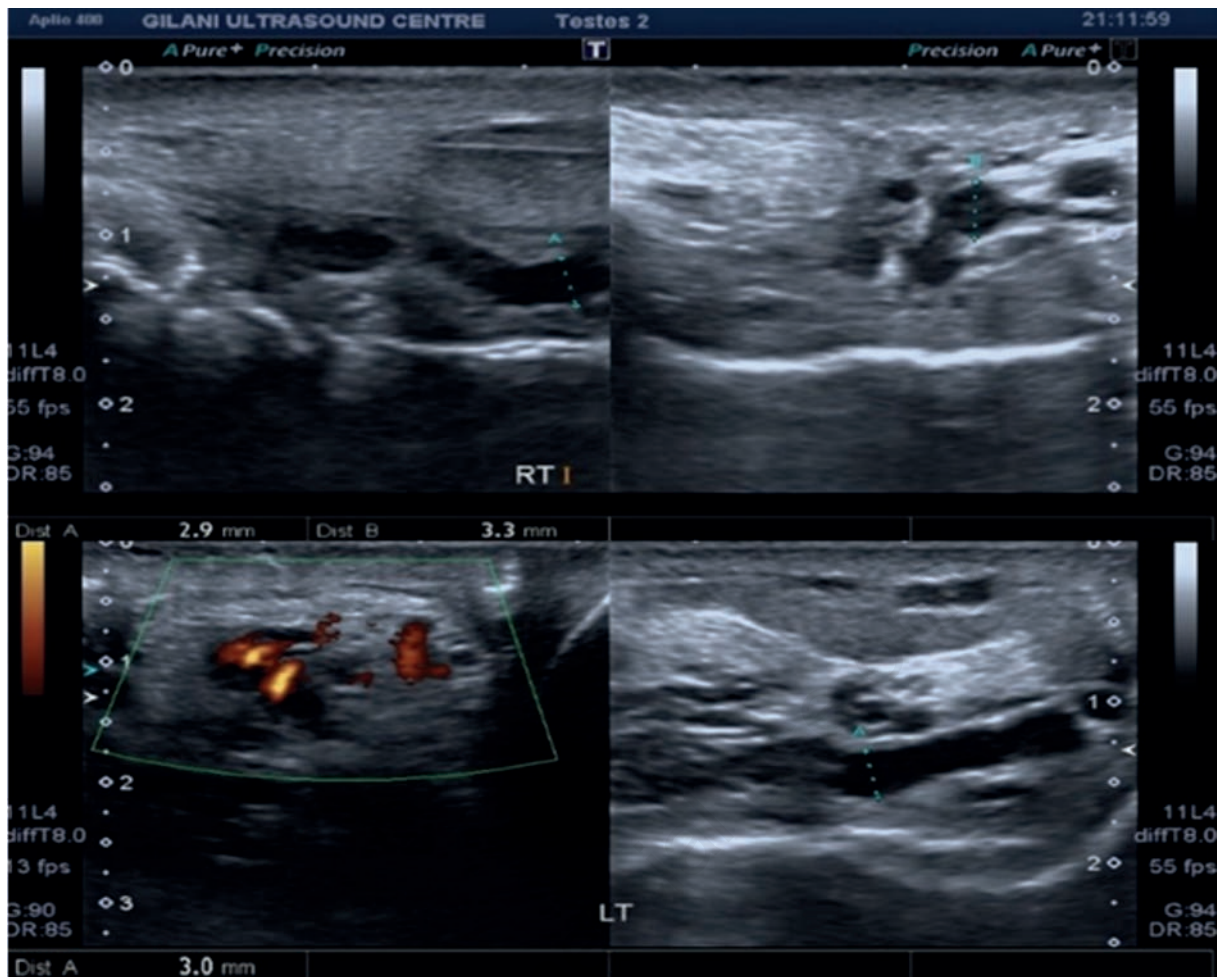


Figure 1. Ultrasound images of a 31-year-old obese patient with varicocele measuring 3.6 mm and 2.9 mm on the right and 3.0 mm on the left.

Table 2. Association between varicocele and infertility.

	Varicocele		Total	p
	No	Yes		
Fertile	107	2	109 (63.4%)	0.0001
Infertile	40	23	63 (36.6%)	
	147 (85.5%)	25 (14.5%)	172	

Table 3. Laboratory findings for varicocele.

Lab findings	Varicocele		Total
	No	Yes	
Abnormal morphology	1	0	1 (0.6%)
Aspermia	2	0	2 (1.2%)
Azoospermia	7	0	7 (4.1%)
Increased pus cells	7	1	8 (4.7%)
Normal	108	2	110 (64.0%)
Oligospermia	21	22	43 (25.0%)
Pus cells	1	0	1 (0.6%)
	147 (85.5%)	25 (14.5%)	172

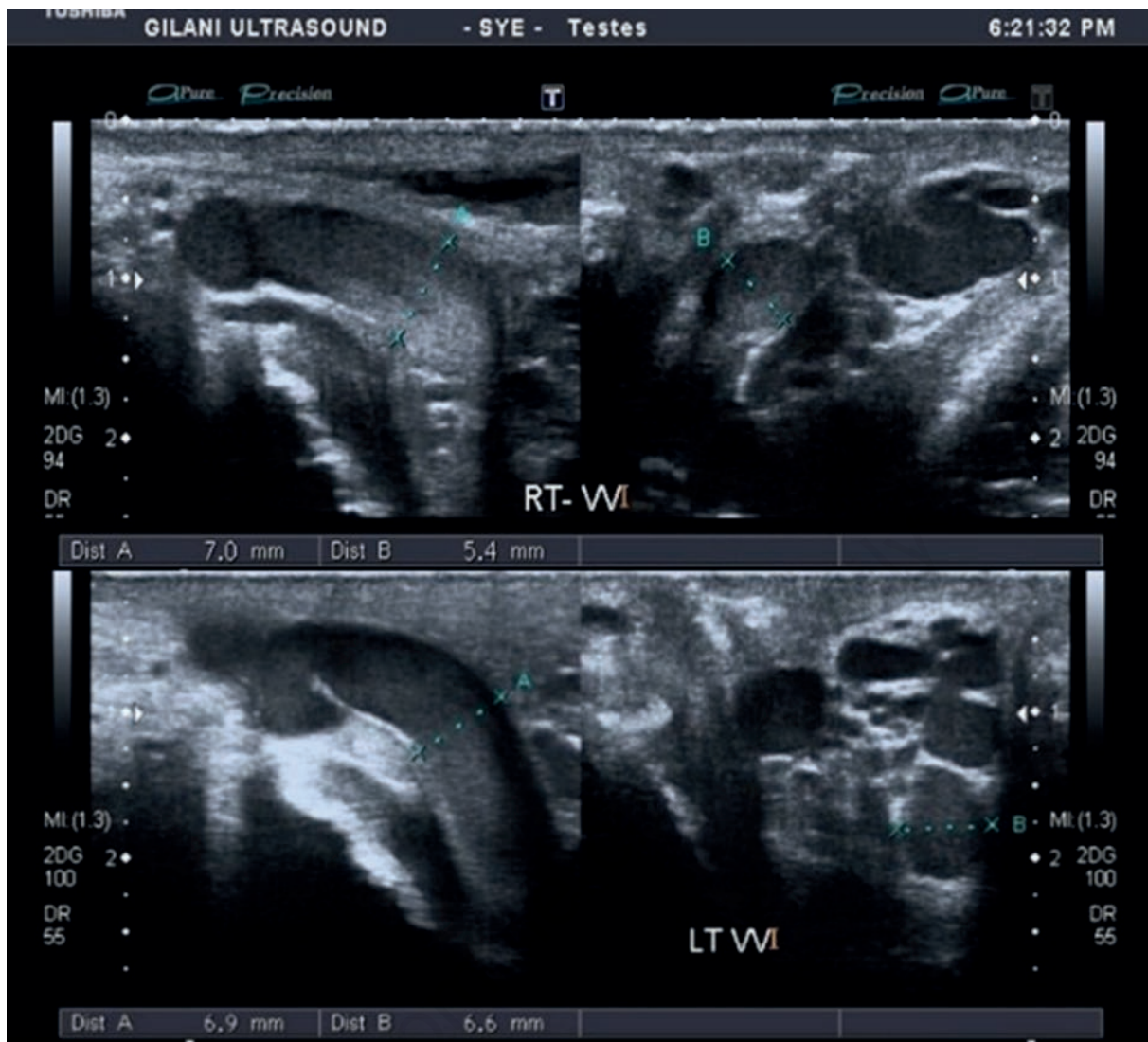


Figure 2. Ultrasound images of a 26-year-old obese patient with a right-sided varicocele measuring 7.0 mm and 5.4 mm; and a left-sided varicocele measuring 6.9 mm and 6.6 mm.

Discussion and Conclusions

The association of varicocele with obesity was estimated: 8 (9.3%) nonobese patients had varicocele, whereas 17 (19.7%) in the obese group had varicocele. In this context, a review was conducted by Chaudhuri *et al.* to determine the influence of obesity on male infertility. Obesity, increased scrotal temperature, and varicosity lead to male infertility.¹⁹ In 2010, a meta-analysis was conducted by Xiao-Bin *et al.* to determine the association between obesity and varicocele as causes of male infertility. However, it concluded that obesity is negatively associated with the presence of varicocele.²⁰ In 2022, a meta-analysis was conducted by Hu *et al.* on the association between varicocele and obesity in the Chinese population. It was concluded that obesity is associated with varicocele in individuals of reproductive age. However, they added that the likelihood

of varicocele varies with position. Furthermore, the effects of weight management and varicocele on fertility should be taken into account in fertility guidance.²¹ The findings of the current study correlate with the literature except for a single study in which varicocele was negatively associated with obesity. Most likely, with an increase in the amount of subcutaneous fat, varicocele has not been properly evaluated. The rest of the studies favor the likelihood of varicocele with obesity.

A study conducted by Guo *et al.* in 2019 analyzed the sperm quality in obese and nonobese individuals. They concluded that semen quality was not sufficiently affected by obesity.²² Another study was conducted by Wang *et al.* in 2021 to determine whether semen quality is affected by obesity. They included known infertile patients in the study samples. It was concluded that obesity affects semen quality to a certain extent and that maintaining normal weight

may be an effective way to improve male fertility.⁶ The relationship between obesity and infertility and its possible mechanism were studied by Chaudhuri *et al.* in 2021. They explained the possible obesity-mediated mechanisms, especially *via* physical factors, OS induction, endocrine modulation, immune alterations, and genetic and epigenetic changes, which may culminate in perturbed spermatogenesis, disrupted sperm DNA integrity, compromised sperm functions, and diminished semen quality, leading to impaired male reproductive functions.¹⁹ The findings of the current study are well correlated with the published data. According to the current study, obesity does not significantly affect male infertility, but it is mildly associated with male infertility.

In the present study, 2 patients had varicocele while they were fertile, and 23 patients had varicocele and an infertility history. In this context, a review was conducted by Jensen *et al.* in 2017 to determine the relationship between varicocele and infertility. Varicocele is considered the most common cause of male infertility, but some men with varicoceles are able to father children, even without intervention. In addition, improvements in semen quality after varicocelectomies do not always result in spontaneous pregnancy. Studies regarding the possible pathophysiological mechanisms behind varicocele-induced infertility have attempted to address these controversies. It was concluded that varicocelectomies have promising effects on semen quality and pregnancy outcomes in couples with documented infertility only if the male partner has a clinically palpable varicocele and affects semen parameters.²³ A review study revealed that varicocele was believed to be the cause of male infertility, but until 1952, the Edinburgh surgeon Selby Tulloch reported restored spermatogenesis in an azoospermic man after excision of bilateral varicoceles. By the 1960s, there was a general belief that varicocele caused infertility and that it did this either by raising the scrotal temperature or by toxic reflux of adrenal steroids. The argument at the time was not about effectiveness but rather about whether it was important to ligate the cremasteric veins or the internal spermatic vein.²⁴ A study was conducted by Alkhalaf *et al.* in 2023 to determine the outcomes of varicocelectomy in the form of pain relief and fertility. For 37 out of 47 of all patients, varicocelectomies for pain led to pain relief.²⁵

References

- Babakhanzadeh E, Nazari M, Ghasemifar S, Khodadadian A. Some of the factors involved in male infertility: a prospective review. *Int J Gen Med* 2020;13:29-41.
- Jawad Z, Mustafa R, Kanwal A, Khan S. Awareness Regarding Causes of Infertility among Out-patients at a Tertiary Care Hospital in Lahore, Pakistan. *Pakistan J of Medical & Health Sciences* 2022;16:227.
- Maheshwari A, Muneer A, Lucky M, et al. A review of varicocele treatment and fertility outcomes. *Hum Fertil* 2022;25:209-16.
- Garolla A, Grande G, Palego P, et al. Central role of ultrasound in the evaluation of testicular function and genital tract obstruction in infertile males. *Andrology* 2021;9:1490-8.
- Gurung P, Yetiskul E, Jialal I. Physiology, male reproductive system. Treasure Island, FL, USA: StatPearls Publishing; 2023.
- Wang S, Sun J, Wang J, et al. Does obesity based on body mass index affect semen quality?—a meta-analysis and systematic review from the general population rather than the infertile population. *Andrologia* 2021;53:e14099.
- Tanga BM, Qamar AY, Raza S, et al. Semen evaluation: methodological advancements in sperm quality-specific fertility assessment—a review. *Anim Biosci* 2021;34:1253-70.
- Billard R, Cosson M. The energetics of fish sperm motility. In: Gagnon C, ed. *Controls of sperm motility*. Boca Raton, FL, USA: CRC Press; 1990. pp 153-73.
- David MK, Leslie SW. Prostate specific antigen. Treasure Island, FL, USA: StatPearls Publishing; 2020.
- Moridi A, Roozbeh N, Yaghoobi H, et al. Etiology and risk factors associated with infertility. *Int J Womens Health Reprod Sci* 2019;7:346-53.
- Delbaere I, Verbiest S, Tydén T. Knowledge about the impact of age on fertility: a brief review. *Ups J Med Sci* 2020;125:167-74.
- Hocaoglu C. The psychosocial aspect of infertility. In: Sheriff DS, ed. *Infertility, assisted reproductive technologies and hormone assays*. London, UK: IntechOpen; 2018.
- Lam IS, Trost LW, Casalino DD, Brannigan RE, 2019. Ultrasound in male infertility. In: Stadtmauer LA, Turkaspa I, ed. *Ultrasound imaging in reproductive medicine: advances in infertility work-up, treatment and ART*. Cham, Switzerland: Springer Cham; 2019. pp 213-35.
- Zubair A, Lotfollahzadeh S. Peripheral arterial duplex assessment, protocols, and interpretation. Treasure Island, FL, USA: StatPearls Publishing; 2022.
- Kang C, Punjani N, Lee RK, et al. Effect of varicoceles on spermatogenesis. *Semin Cell Dev Biol* 2022;121:114-24.
- Spaggiari G, Granata AR, Santi D. Testicular ultrasound inhomogeneity is an informative parameter for fertility evaluation. *Asian J Androl* 2019;22:302-8.
- Lotti F, Bertolotto M, Maggi M, 2021. Historical trends for the standards in scrotal ultrasonography: What was, what is and what will be normal. *Andrology* 2021;9:1331-55.
- Tsili AC, Bougia CK, Pappa O, Argyropoulou MI. Ultrasonography of the scrotum: revisiting a classic technique. *Eur J Radiol* 2021;145:110000.
- Chaudhuri GR, Das A, Kesh SB, et al. Obesity and male infertility: multifaceted reproductive disruption. *Middle East Fertil Soc J* 2022;27:8.
- Xiao-Bin G, Fang-Lei W, Hui X, et al. The association between body mass index and varicocele: A meta-analysis. *Int Braz J Urol* 2020;47:8-19.
- Hu X, Yang X, Zhao J, et al. Association between body mass index and varicocele among 211 989 Chinese reproductive-age males. *Int J Urol* 2022;29:853-9.
- Guo D, Xu M, Zhou Q, et al. Is low body mass index a risk factor for semen quality? A PRISMA-compliant meta-analysis. *Medicine* 2019;98:e16677.
- Palani A, Cannarella R, Saleh R, et al. Impact of varico-

- ocele repair on assisted reproductive technique outcomes in infertile men: a systematic review and meta-analysis. *World J Mens Health* 2024. doi: 10.5534/wjmh.240132.
24. Esteves SC. Pro: should varicocele be repaired in azoospermic infertile men?. In: Esteves SC, Cho CL, Majzoub A, Agarwal A, eds. *Varicocele and male infertility: a complete guide*. Cham, Switzerland: Springer Cham; 2019. pp 485-93.
25. Alkhayal A, Aljumaiah S, Alhagbani A, et al. Varicocelectomy for scrotal pain: is it effective? *Urol Ann* 2023;15: 311-4.

Non-commercial use only